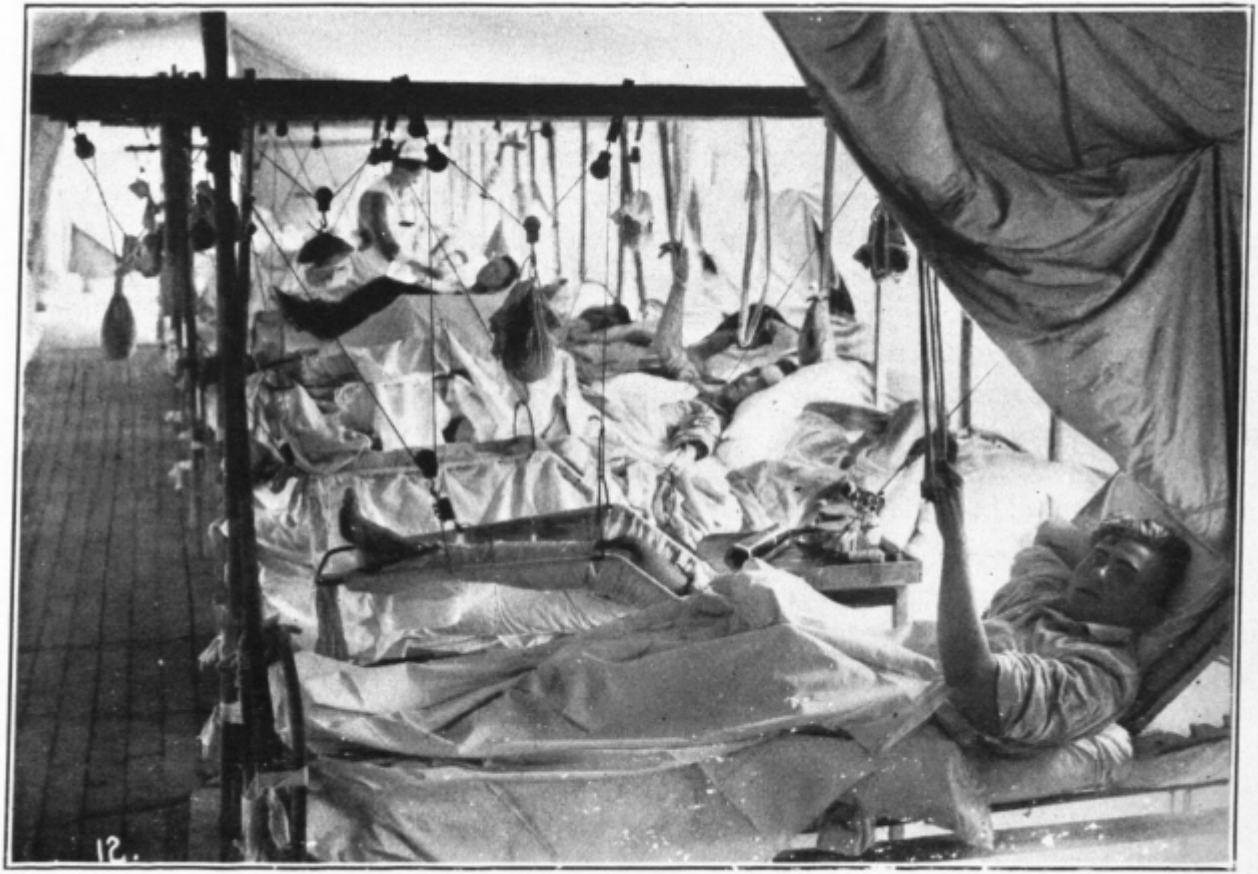

Fig. 96.—Fracture ward of an evacuation hospital