

CHART SHOWING ENTRY WOUND OF 163 PENETRATING  
WOUNDS OF THE ANTERIOR HALF OF THE CHEST.

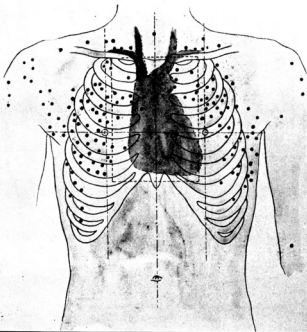


FIG. 4.—Diagram showing anterior portion of chest. Heart and roots of large vessels are indicated