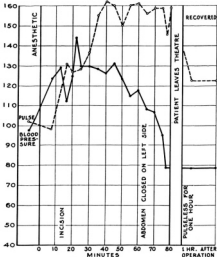


WARM ETHER VAPOR AND OXYGEN
SHELL WOUNDS, ABDOMEN AND LEG
SUTURE OF HOLES IN SMALL GUT
AND COLON



NITROUS OXIDE AND OXYGEN
WITH NOVOCAINE INFILTRATION
PATIENT PALE
SHELL WOUNDS, ABDOMEN AND CHEST-4½ HRS.
LARGE HOLE IN DIAPHRAGM, STOMACH AND
SPLEEN IN THORAX. MUCH BLOOD IN PERITONEUM

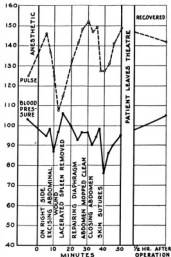


CHART IV.—Comparative effects of ether and of nitrous oxide in operations for the repair of extensive abdominal wounds. Note the greater extent of the trauma in the second case, which received nitrous oxide. (By courtesy of Capt. Geoffrey Marshall, R. A. M. C.)