

PLANTAR

DORSAL

LATERAL

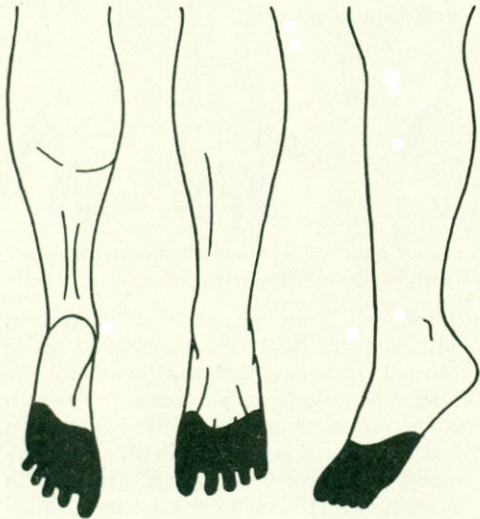


FIG. 94.—Case 12: Nerve readings made six months after suture of sciatic nerve; deep pressure sensation absent in shaded area