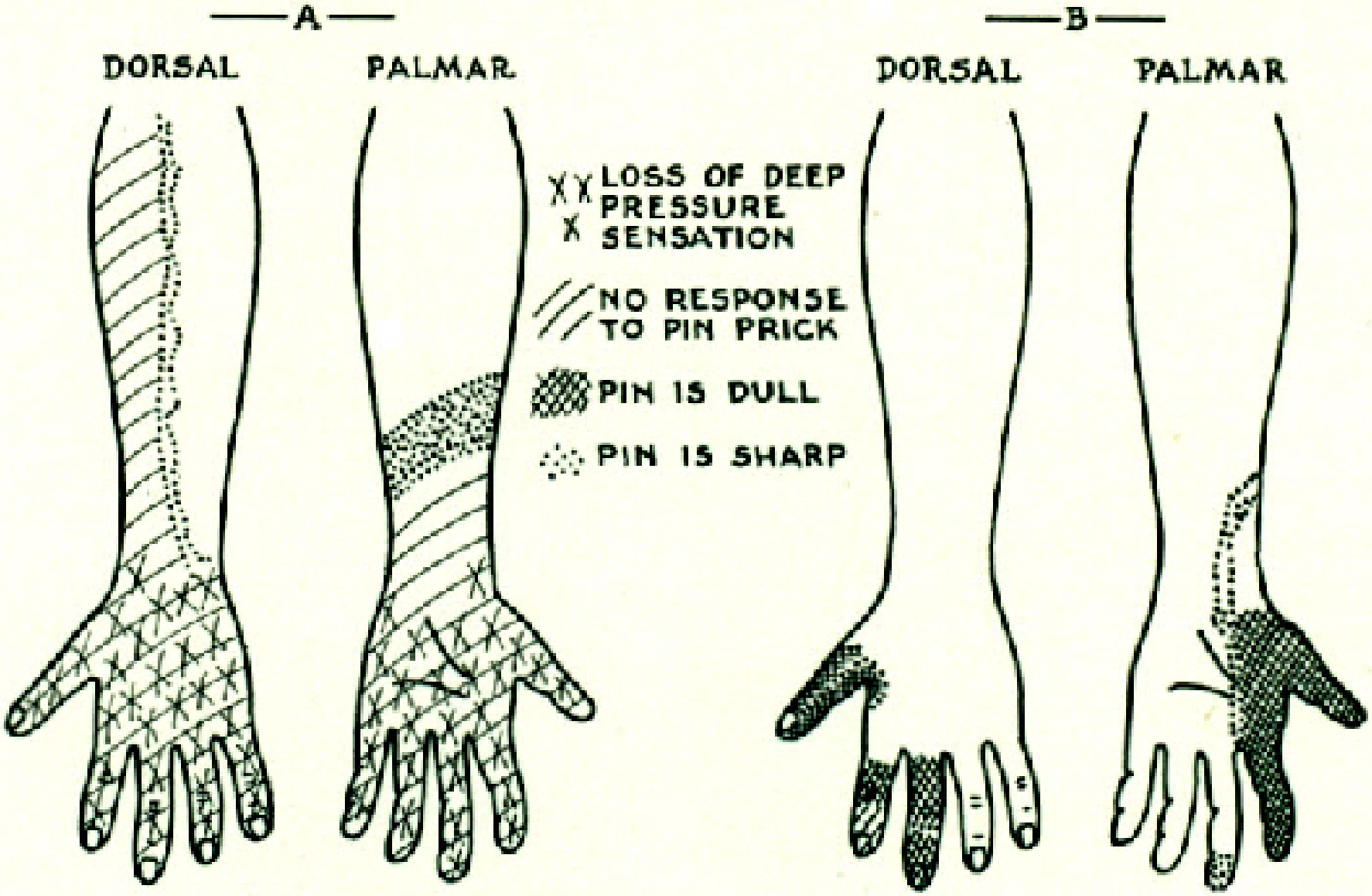

FIG. 90.—Case 9: Nerve readings made (A) before and (B) 13 months after suture of median musculospiral and musculocutaneous nerves