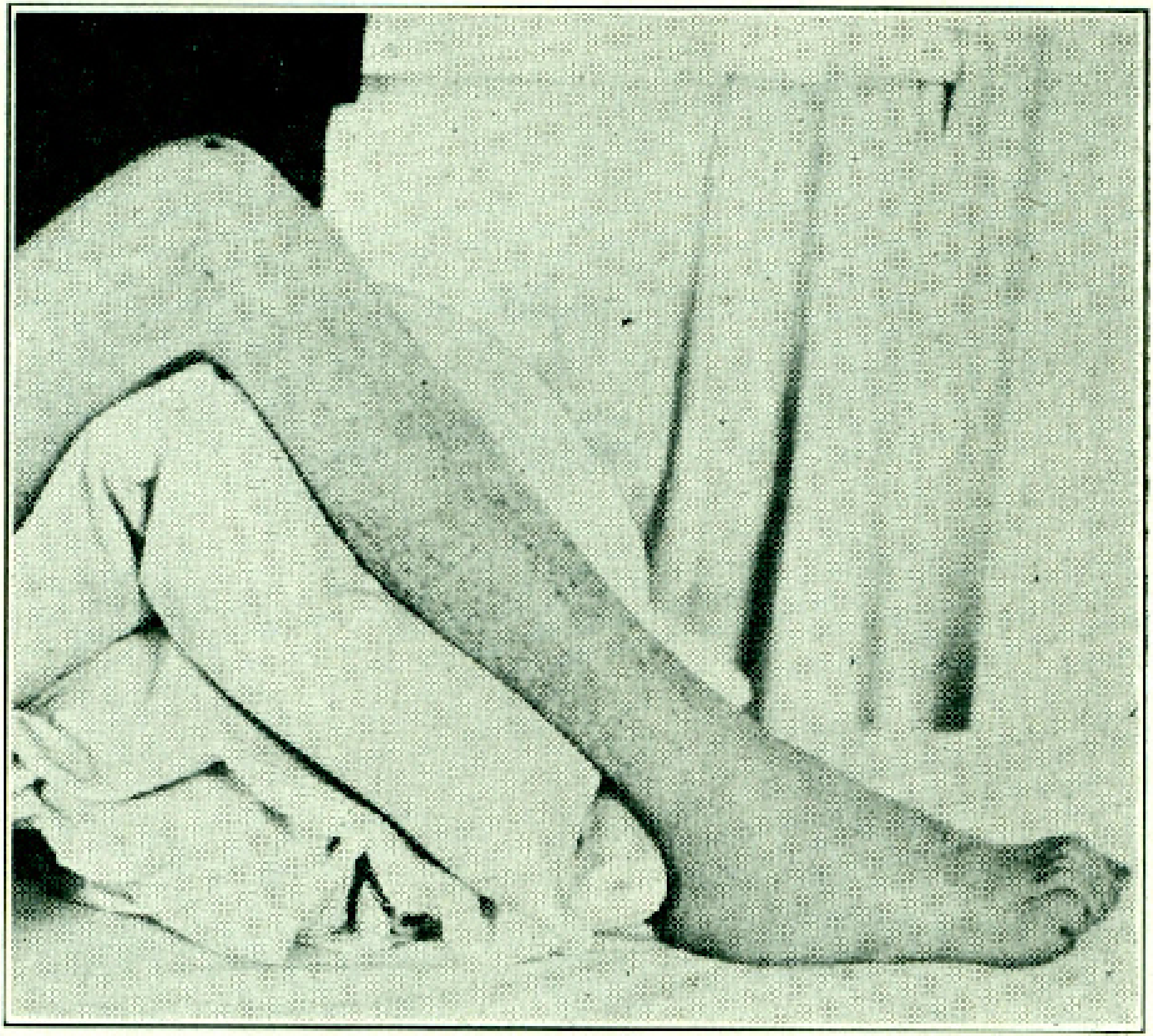

FIG. 87.—Contracture of uninjured right knee after 18 months' confinement to bed