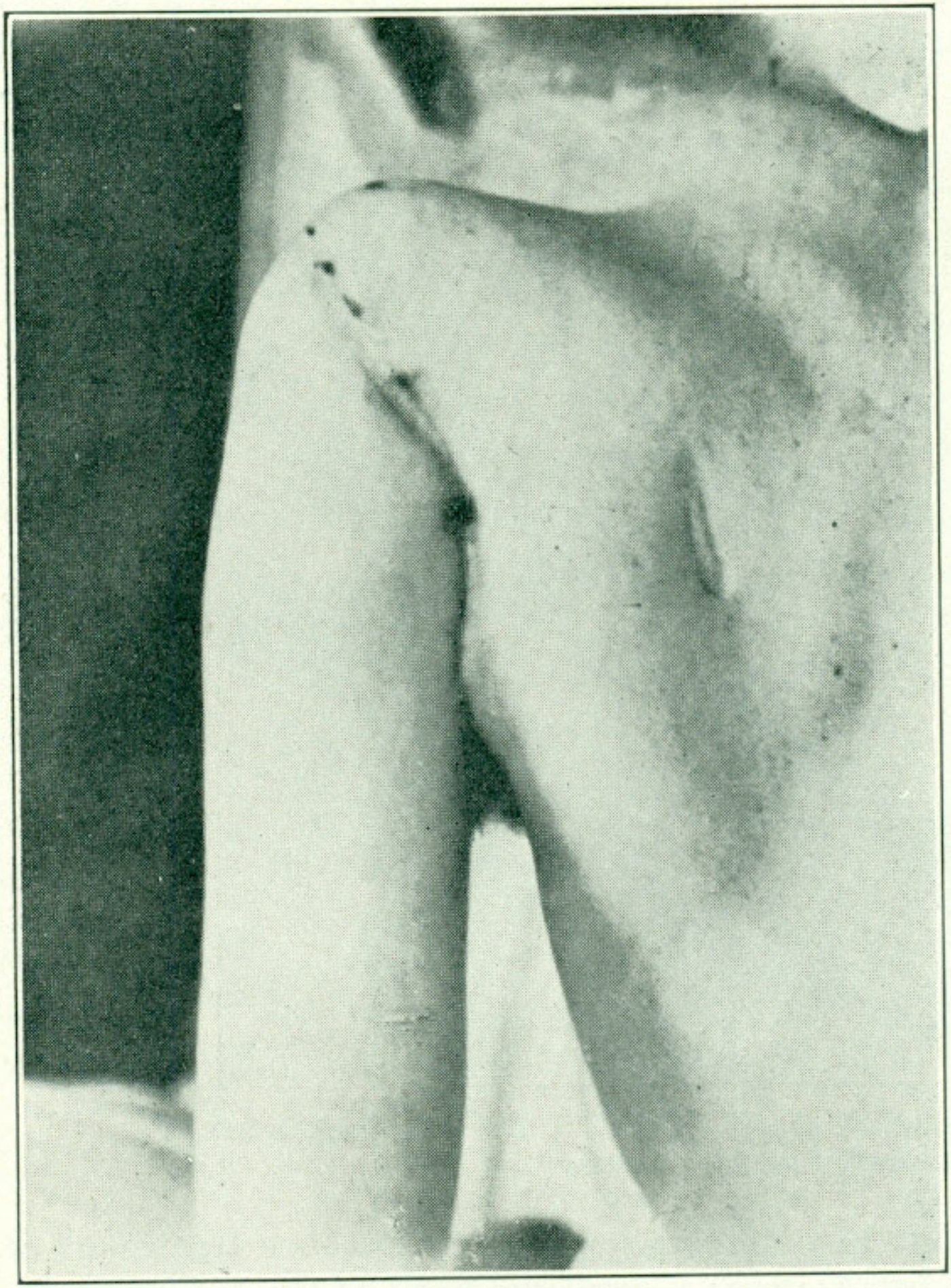

FIG. 86.—Posterior view, left shoulder