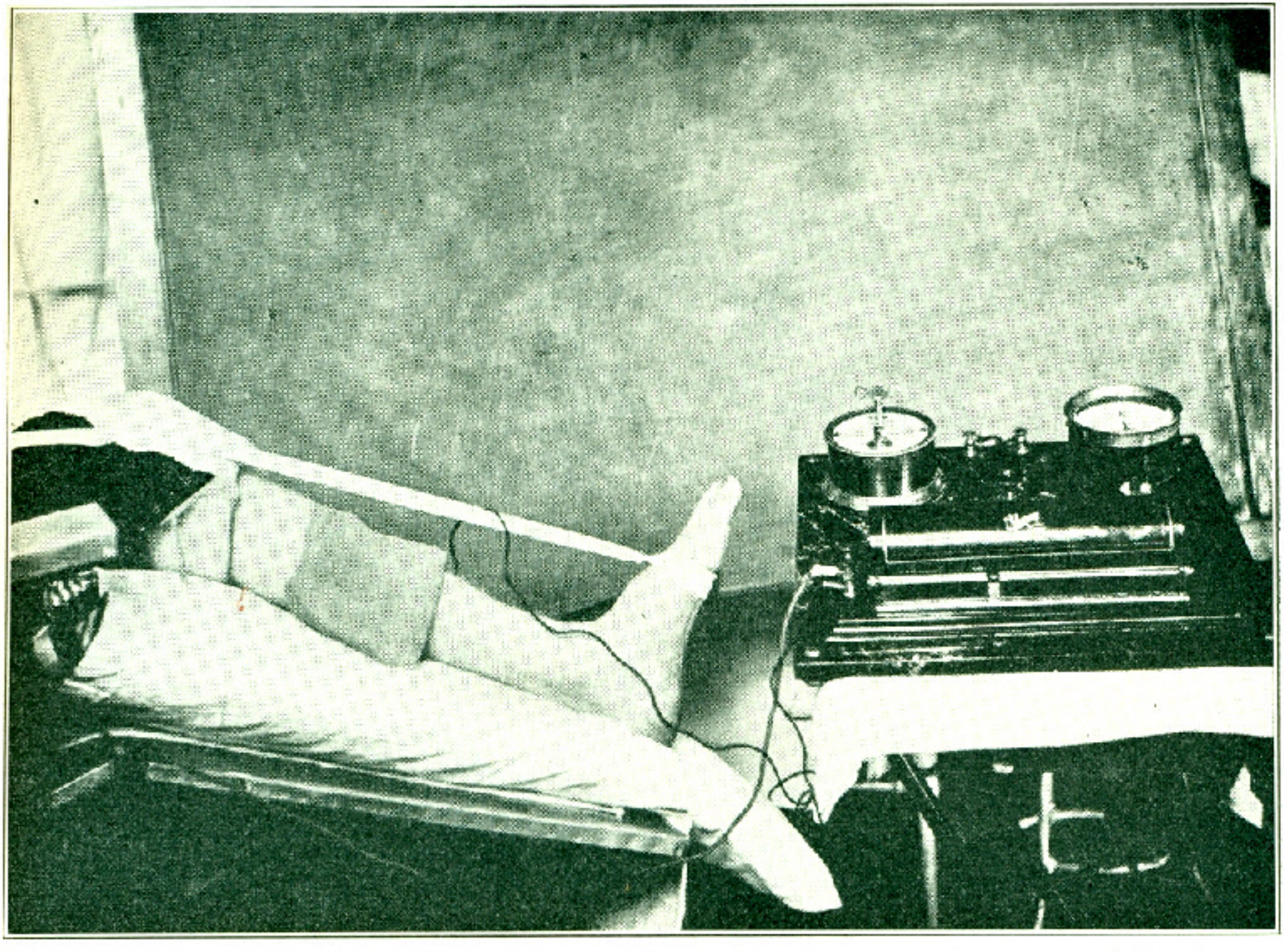

FIG. 67.—Interrupted galvanic current to muscles in case of injury to the external popliteal nerve, with foot drop