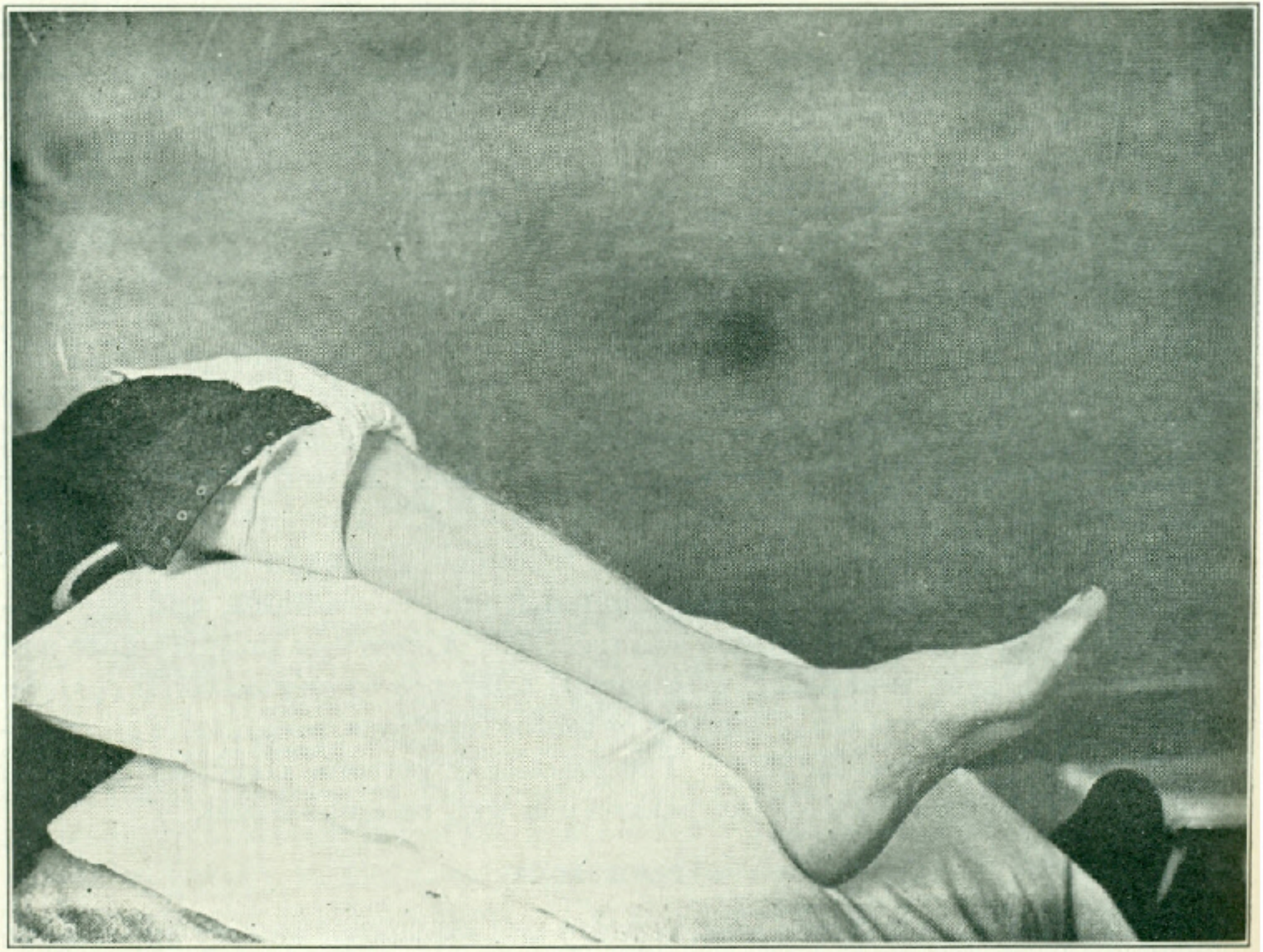

FIG. 53.—Ischemic atrophy, common after nerve injuries and one of the conditions most resistant to physiotherapy