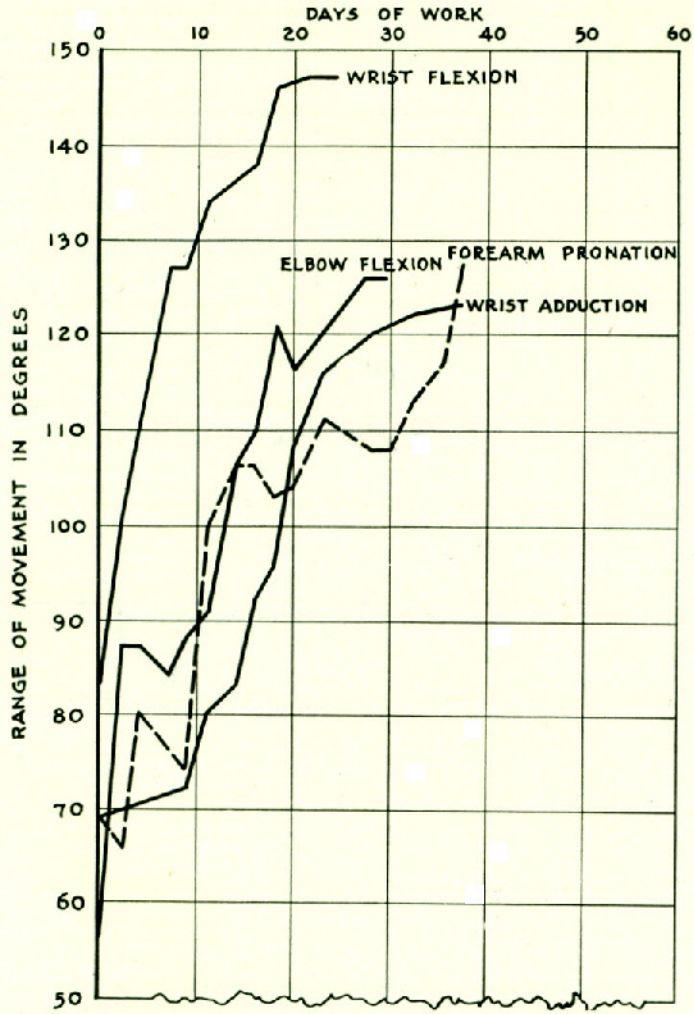

CHART XI.—Improvement curve during 37 days of typewriting and woodworking after bone graft of ulna and radius for gunshot wound, lower third, right forearm