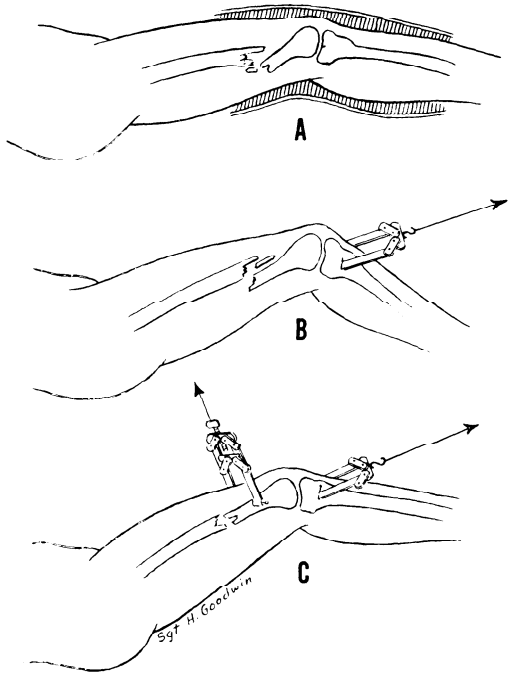

AFIP CB-44-55

FIGURE 54.—Diagrammatic showing of two-wire skeletal traction for battle fracture of femur. A. Deformity on admission to fixed hospital. B. Incomplete reduction in skeletal traction with wire in tibial tubercle. C. Adequate reduction after additional wire has been inserted in lower femoral fragment and vertical lift has been secured.