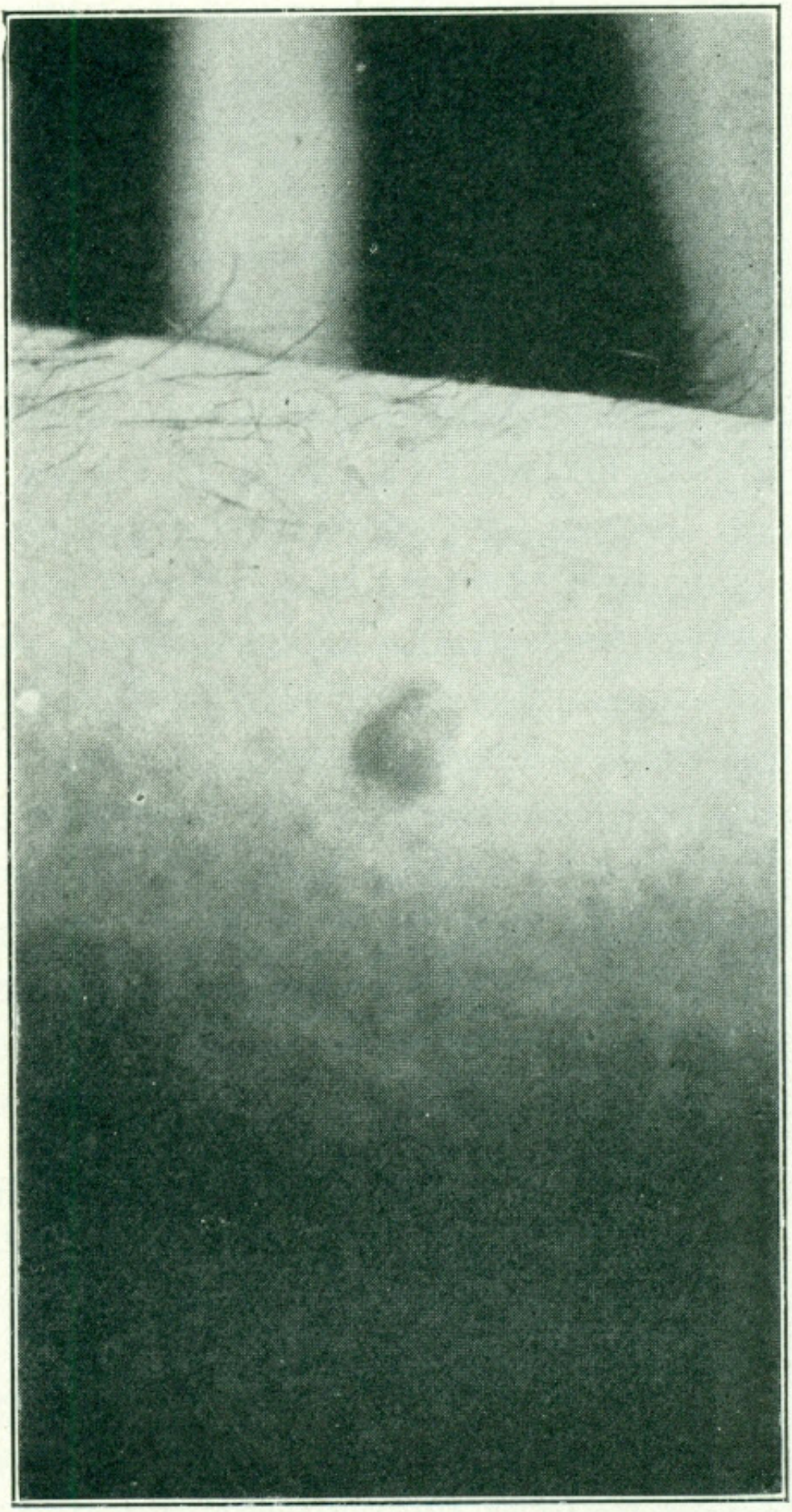

FIG. 93.—Mustard-gas lesion at three hours