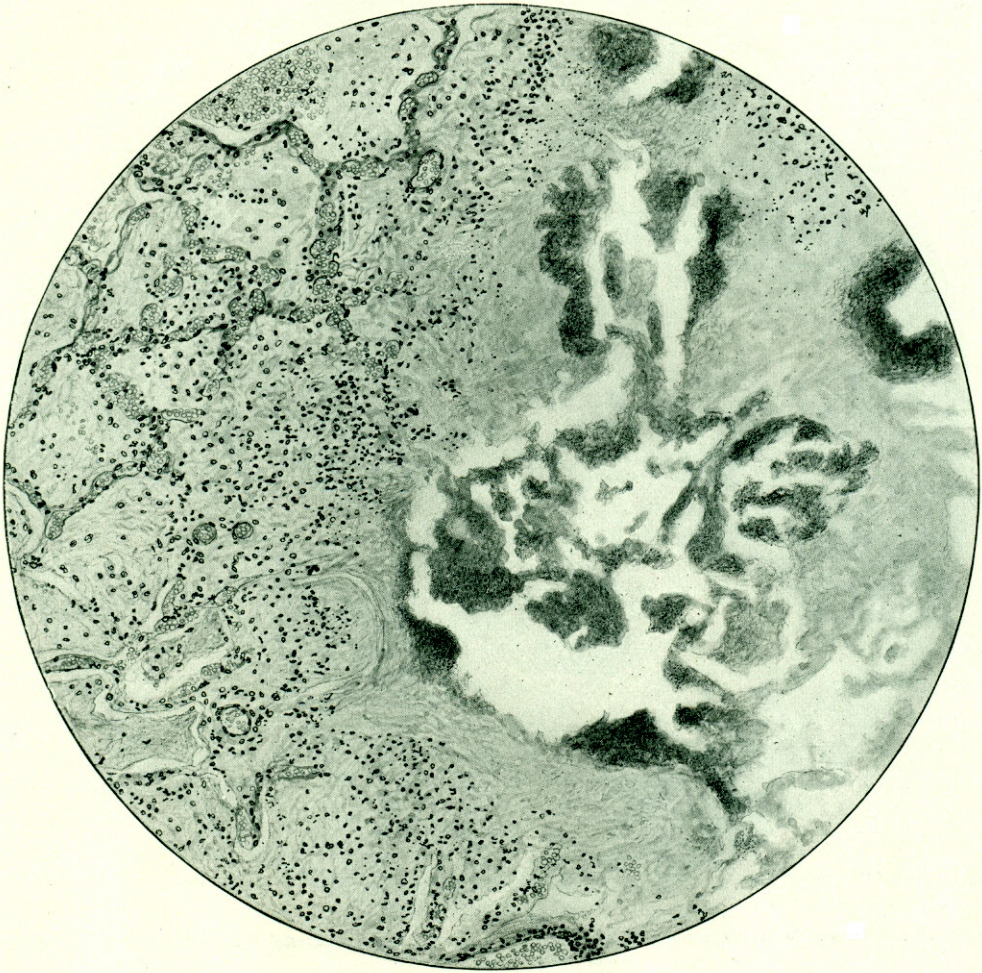

FIG. 36.—Same as Fig. 35. Larger area of gangrene in lung