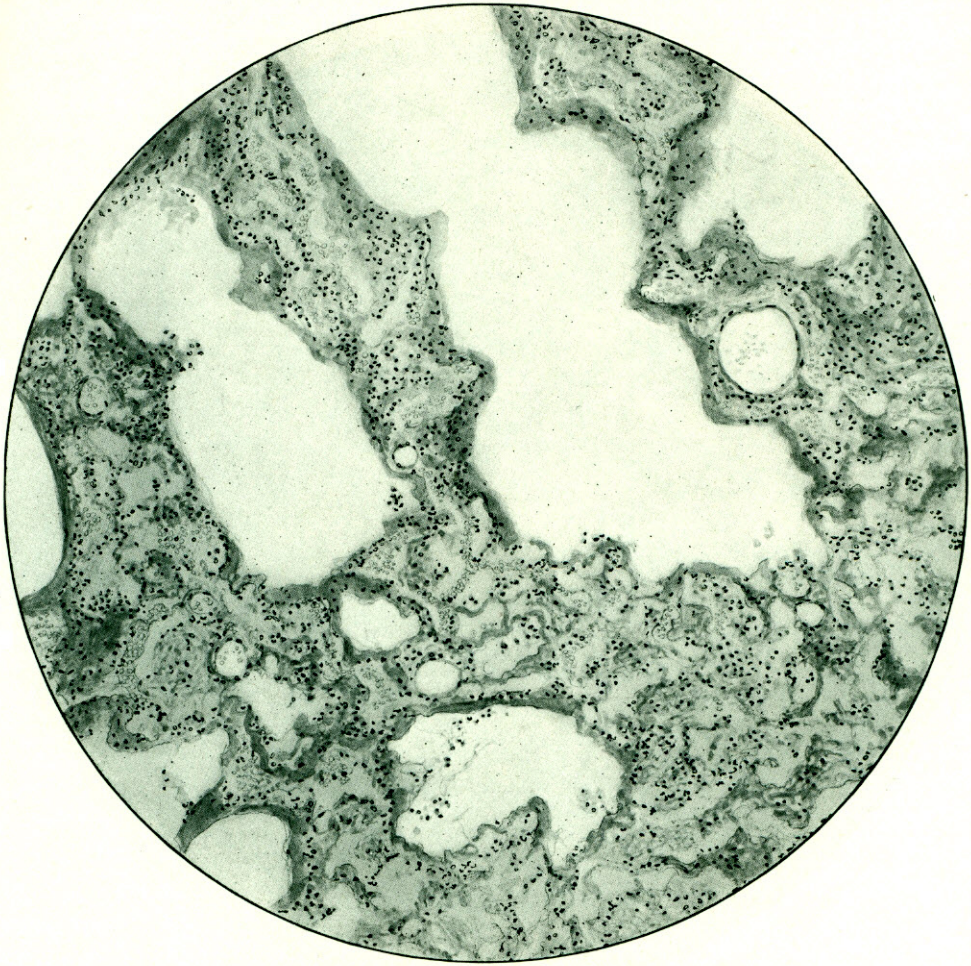

FIG. 22.—Case 81. Mustard-gas burn, 15 days' duration. Lung. Dilatation of atria, with hyaline necrosis