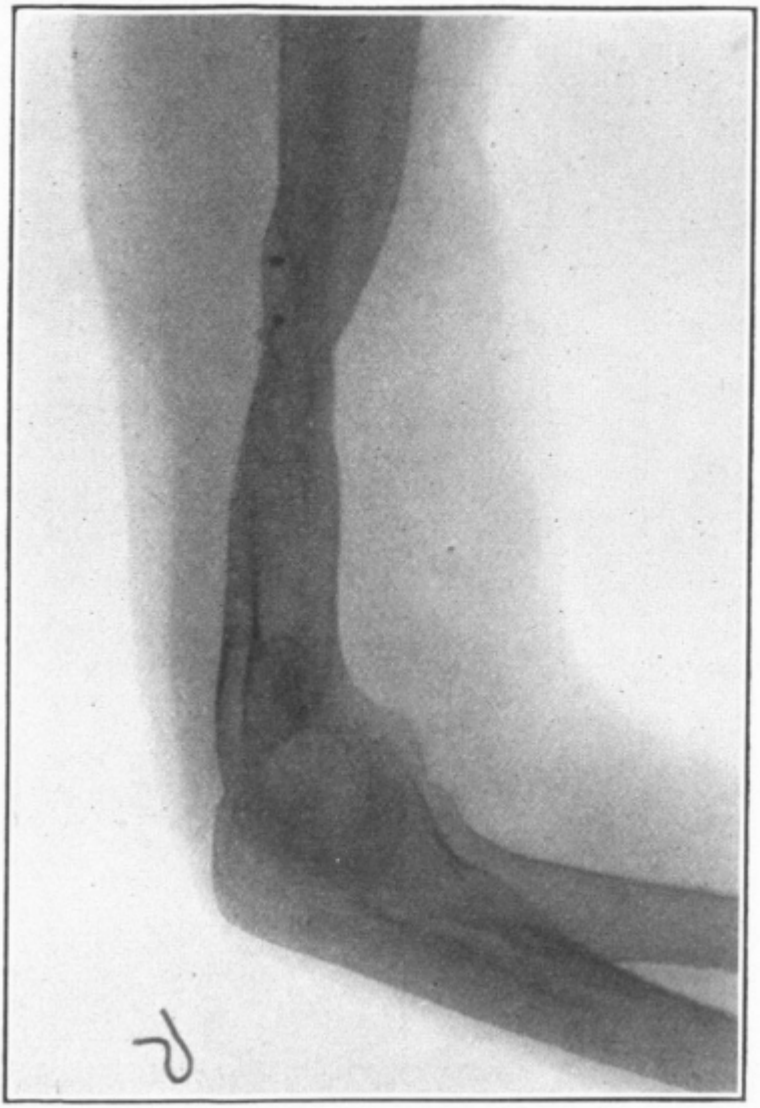

FIG. 107.—Case 8. Excellent bony union at end of six months