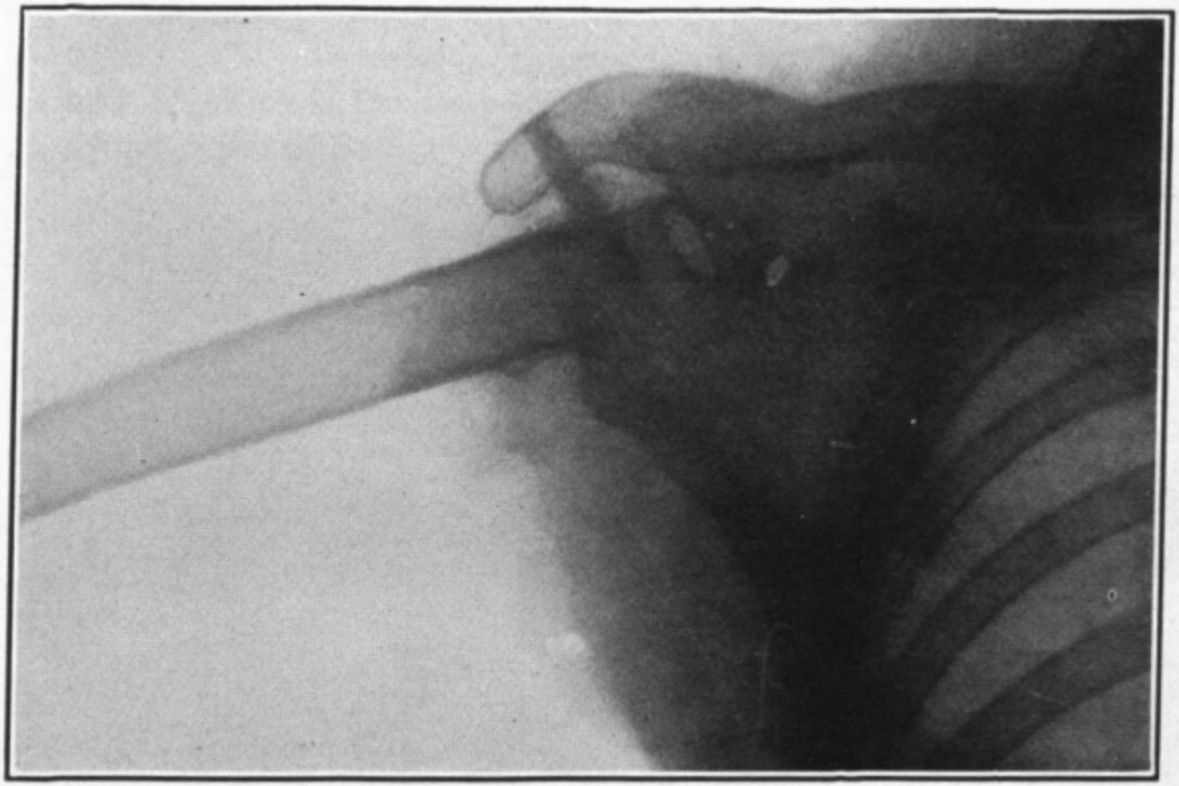

FIG. 100.—Case 6. Good bony union six months after arthrodesis