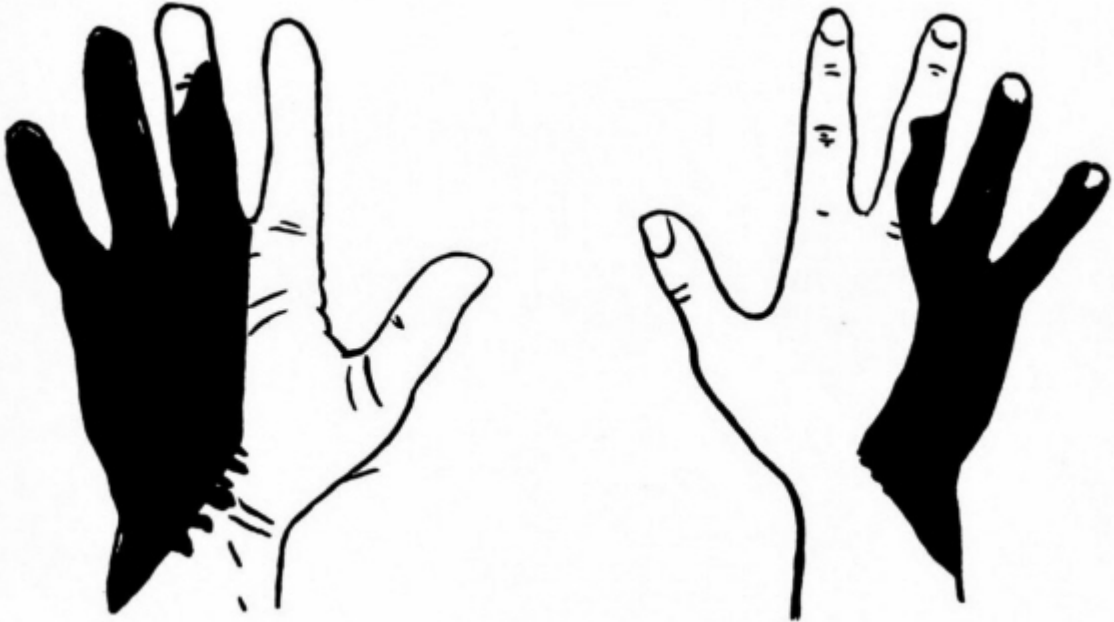

FIG. 142.—Residual sensibility to prick pain of the ulnar nerve