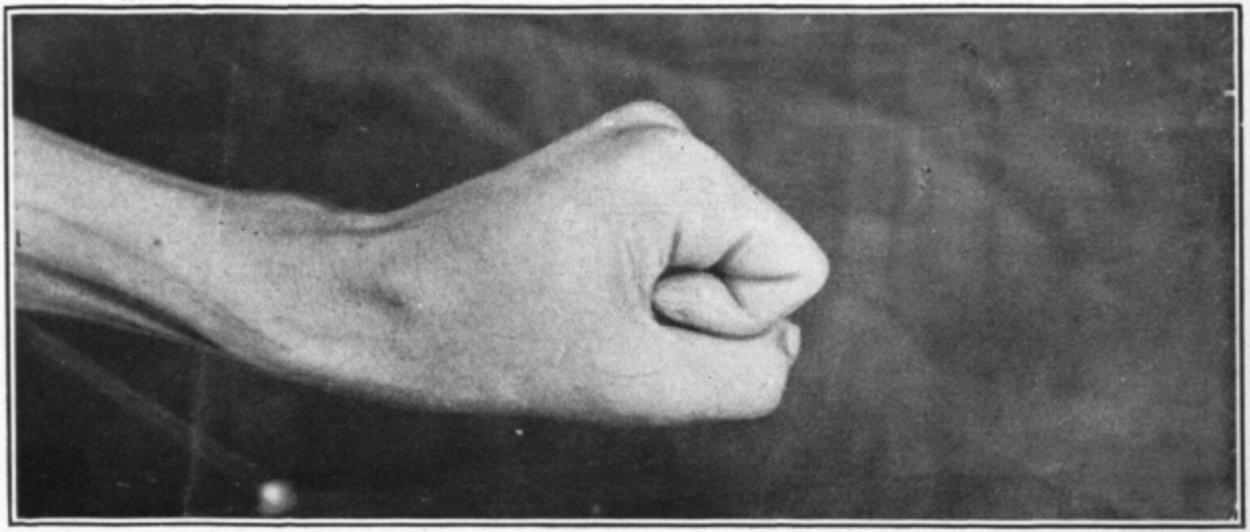

FIG. 102.—Closure of fist in recovered median palsy