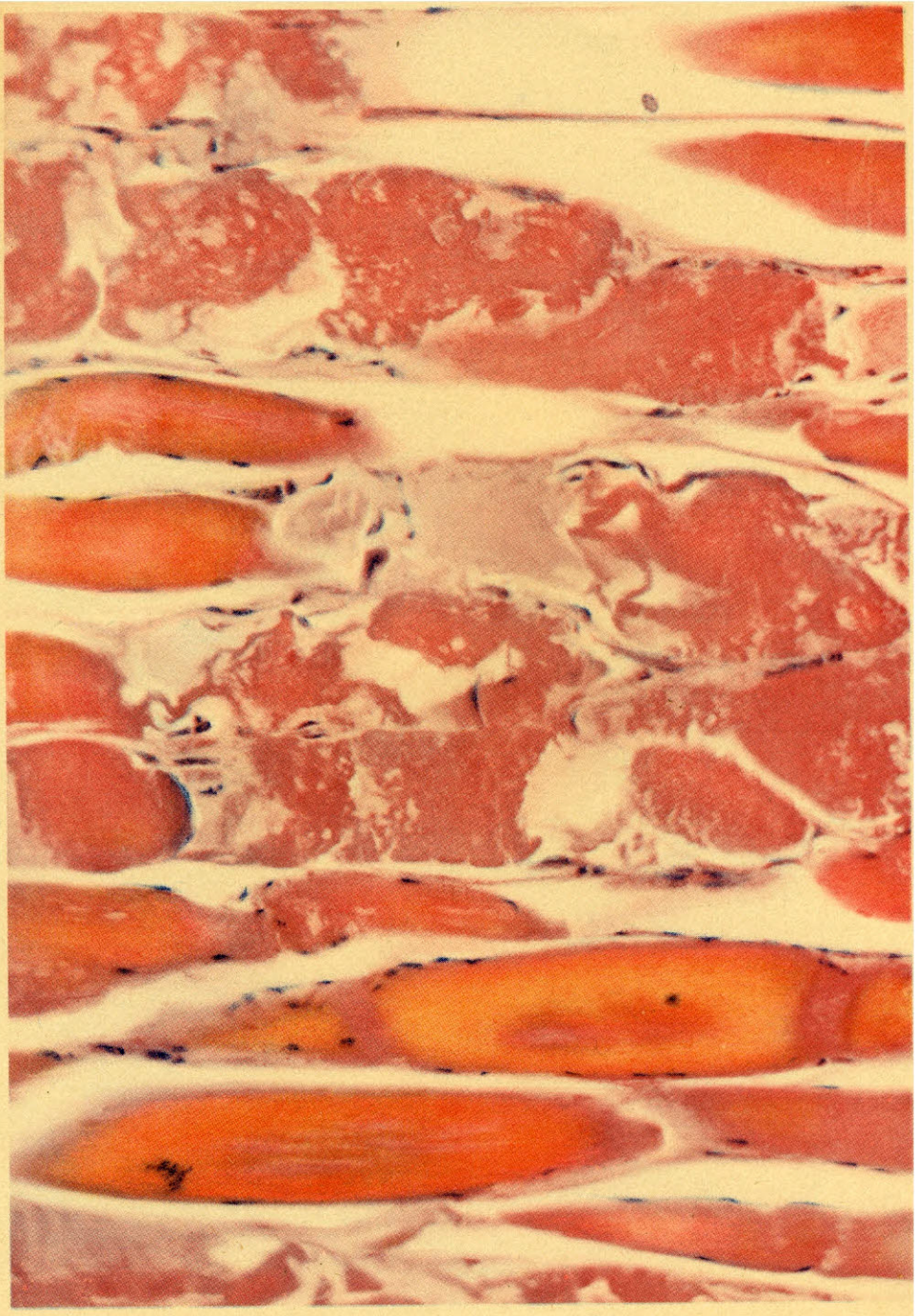

ZENKER'S DEGENERATION OCCURRING IN INFLUENZA.

Accession 6951, Army Medical Museum. Weigert hematoxylin picro-eosin stain. Autochrome.