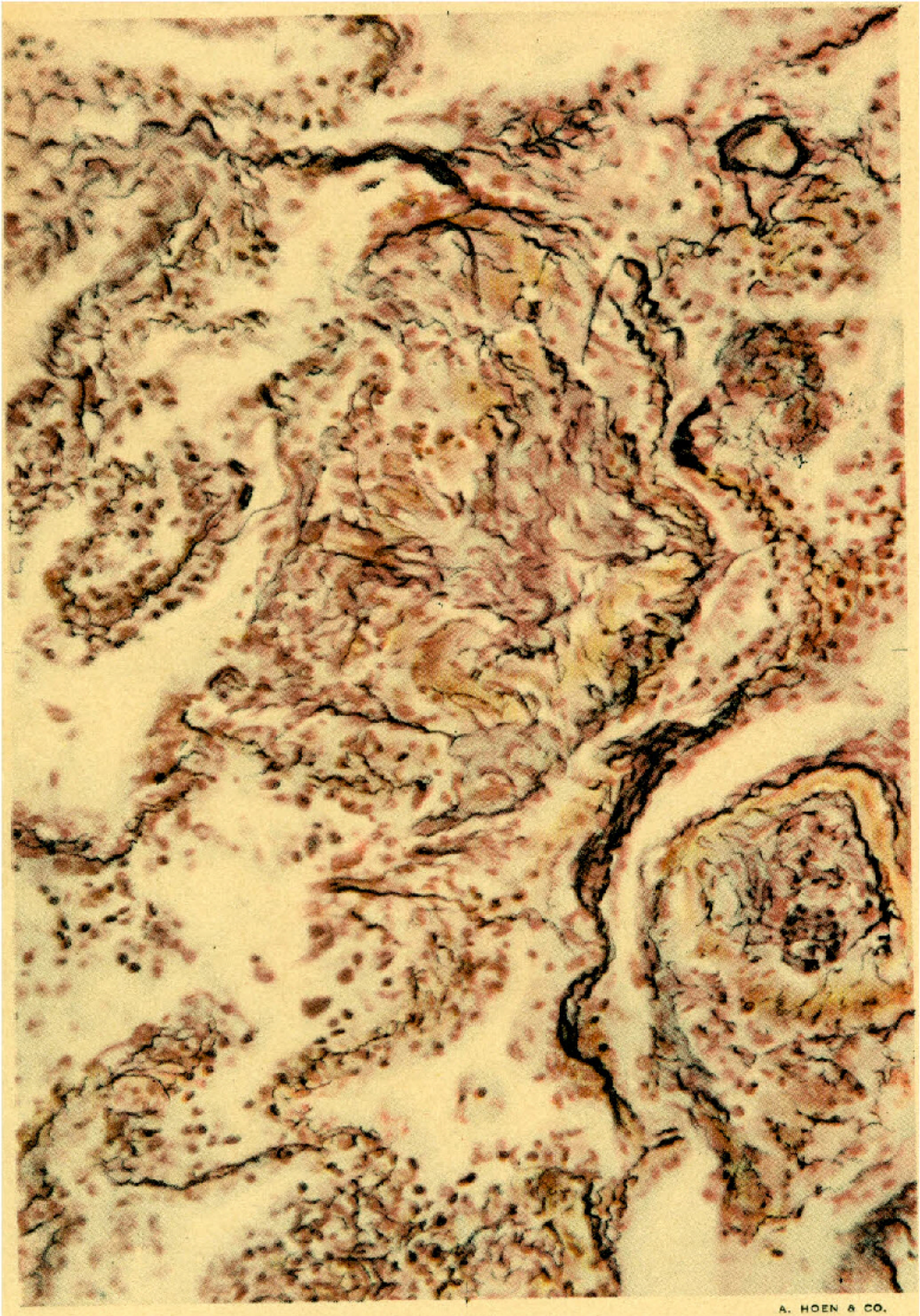

POST INFLUENZAL ORGANIZATION.

Accession 1390, Army Medical Museum. Reticulum stain. Autochrome.