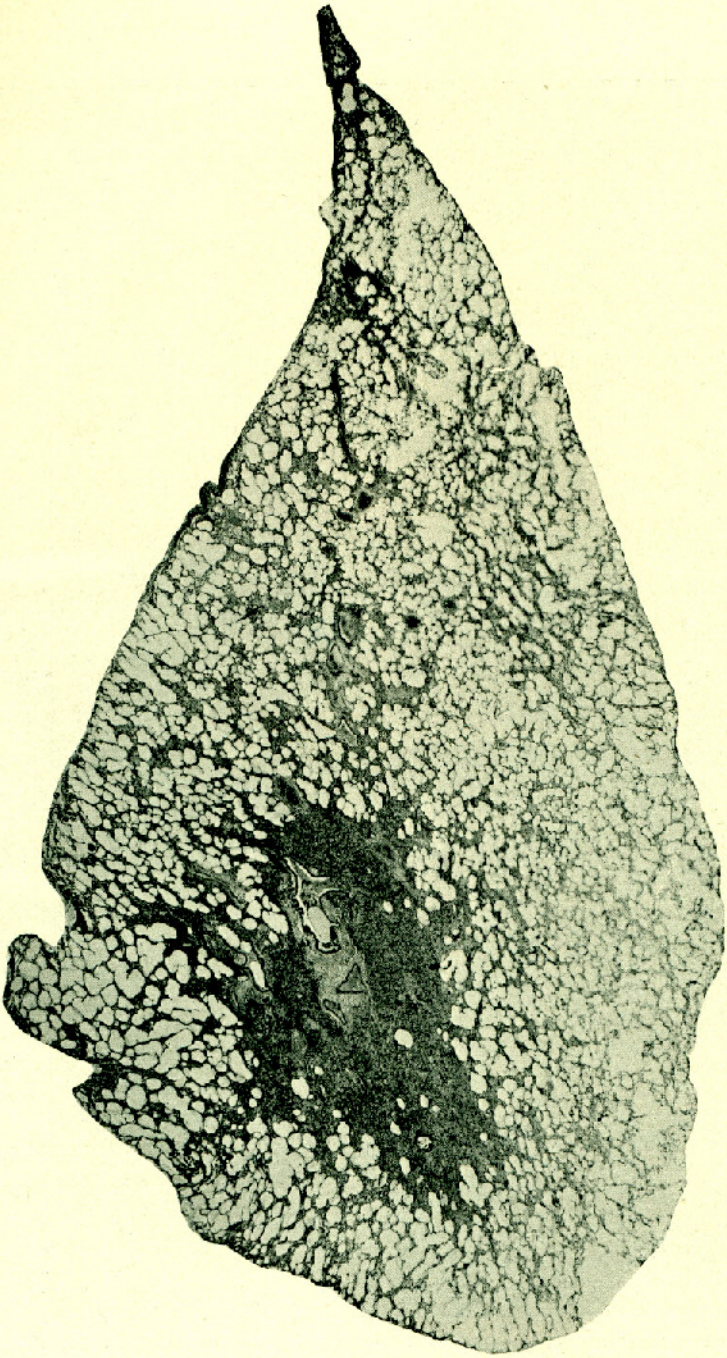

FIG. 77.—Experimental bronchopneumonia in a monkey (No. 112) following injection of 0.01 c. c. pneumococcus, Type I, into the trachea. Bronchopneumonia spreading out from a purulent bronchitis into the alveoli and involving neighboring bronchi. Army Medical Museum, negative number 45493. Hematoxylin and eosin stain; × 5