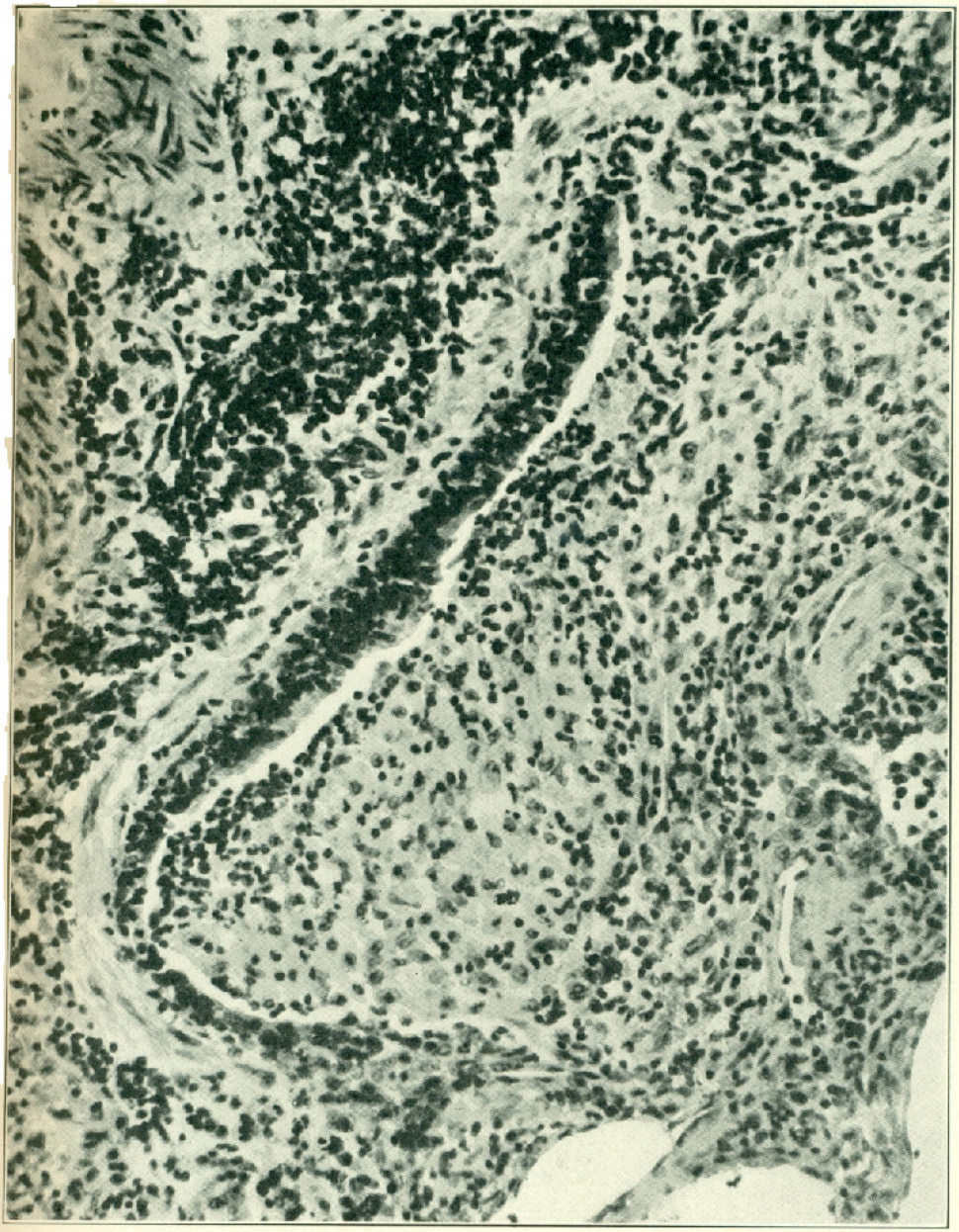

FIG. 69.—New fibrous tissue encroaching on the lumen of a bronchiole in the process of organization. The surface is still free of epithelium but a small lumen remains. Blocks of bronchioles of this character were responsible for atelectatic areas beyond the point of block, and represent the results of the organizing process arising from the ulceration of the bronchiolar mucosa or extending in from alveoli which opened into respiratory bronchioles. Accession number 3061, Army Medical Museum. Negative number 45193. Hematoxylin and eosin stain; × 300