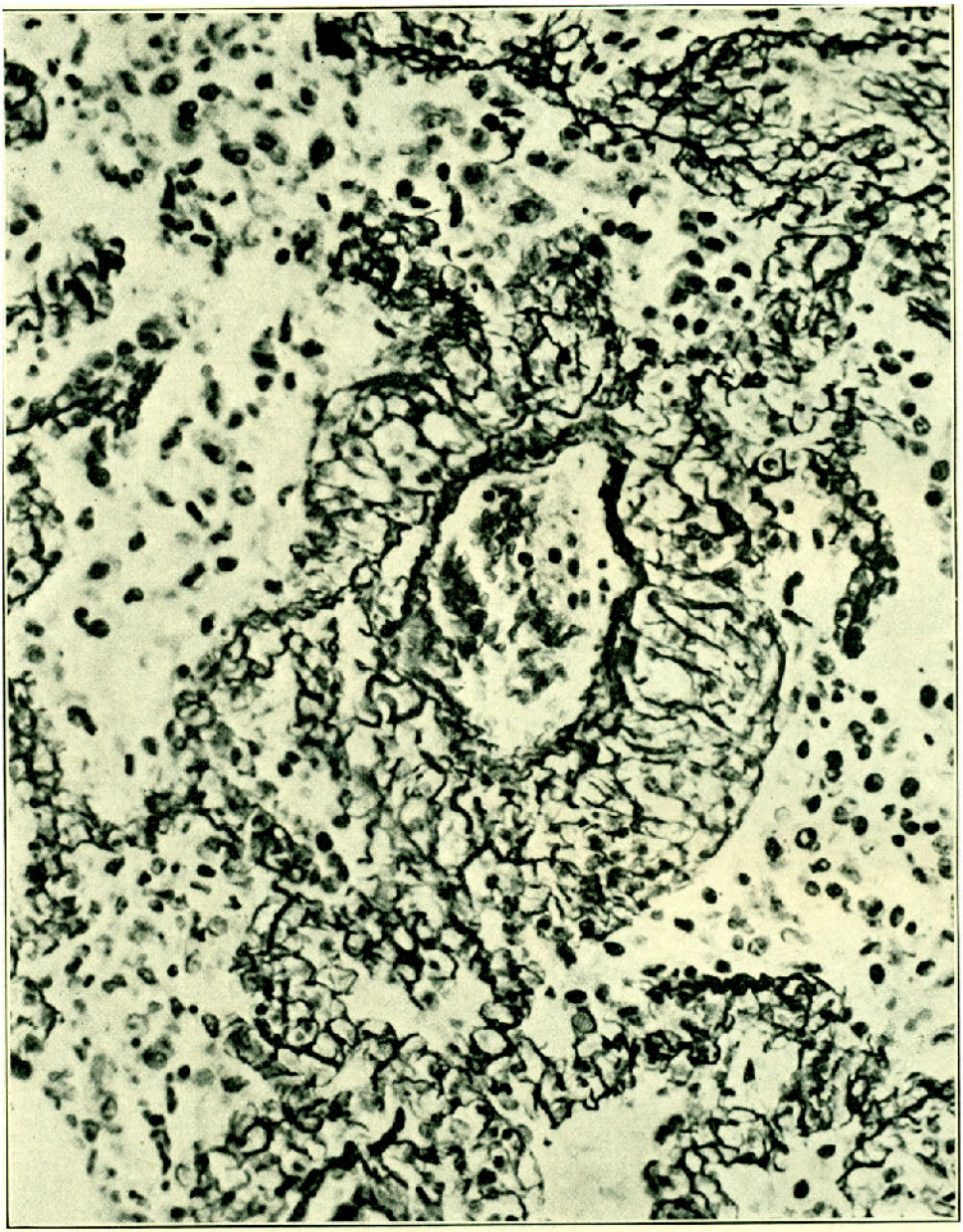

FIG. 64.—Newly formed capillaries about a small blood vessel in the wall of a respiratory atrium, with increase in the number of blood vessels in the alveolar and atrial walls in the vicinity. Accession number 3036, Army Medical Museum. Negative number 45674. Reticulum stain; × 335