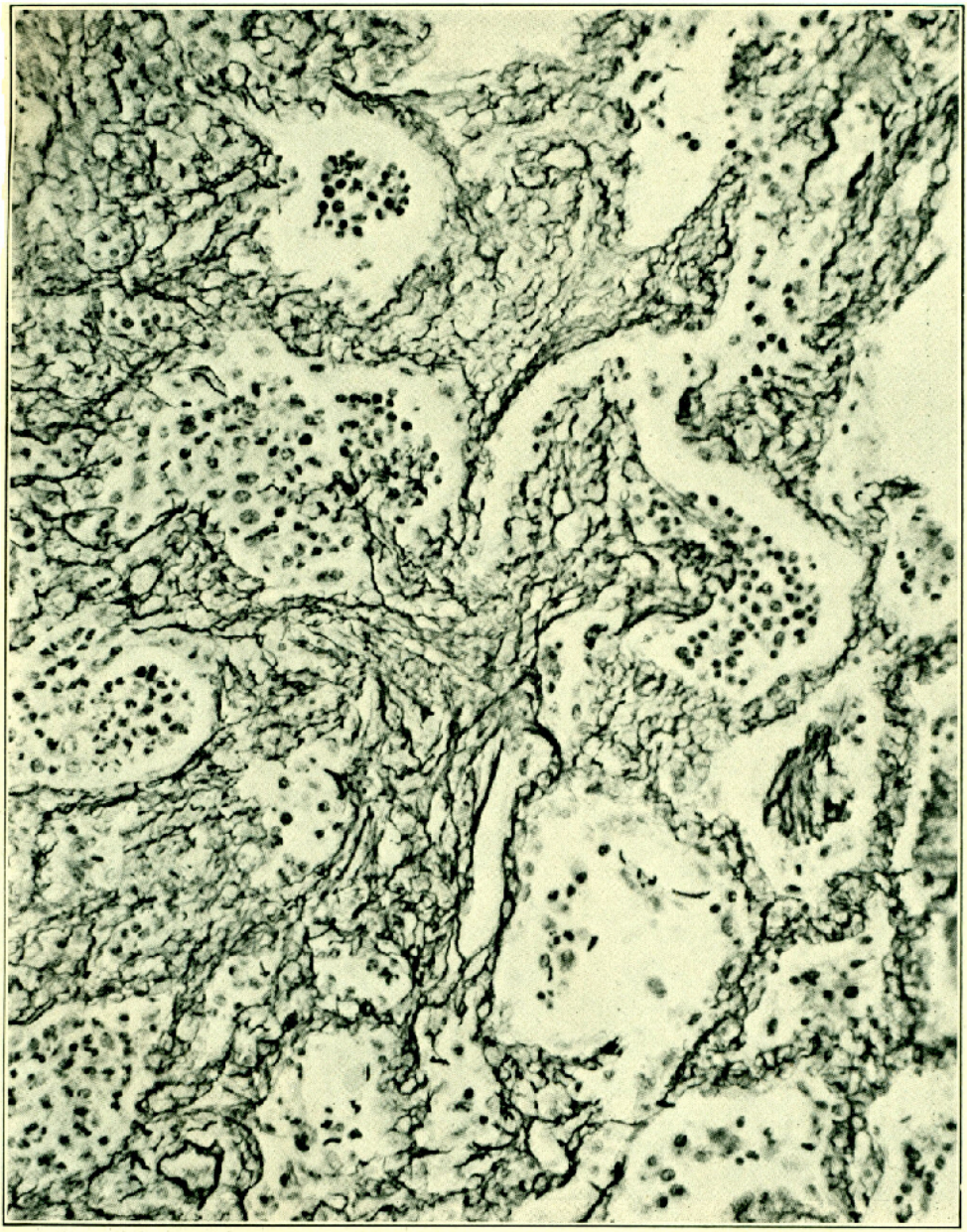

FIG. 59.—Organization of exudate in influenzal pneumonia. The central mass of organization shows dense fibers of reticulum stained black; the lighter lavender fibers are collagen which appears to be laid down between the reticulum fibers, which gradually disappear. In the cellular exudate in two of the alveoli reticulum fibers are extending and in the advanced parts of the extending organization no collagenous fibers can be seen. Accession number 3036, Army Medical Museum. Negative number 45671. Reticulum stain; × 250