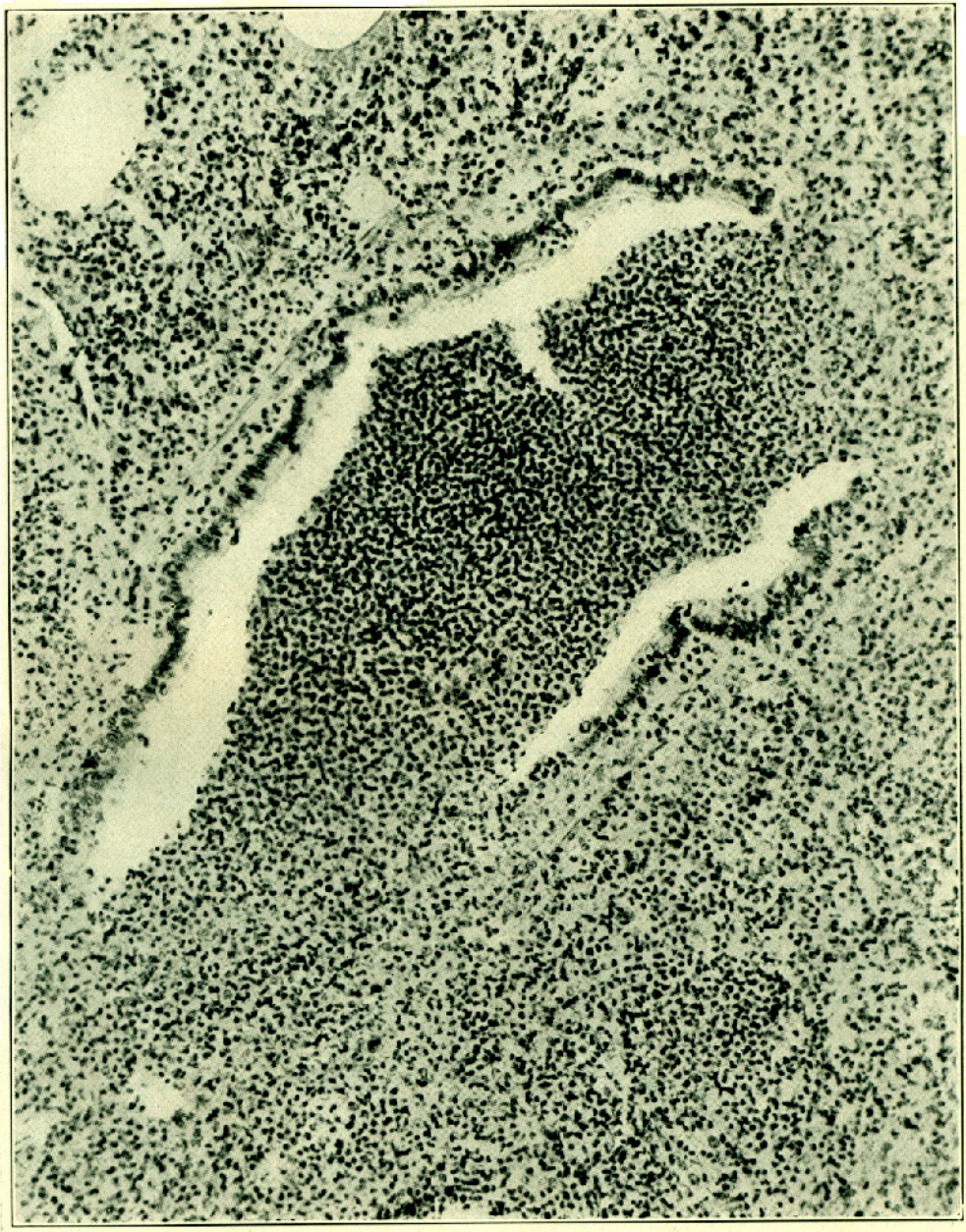

FIG. 43.—A bronchiole, showing absence of columnar cells at either side, the fibrinopurulent exudate being attached where epithelium is absent; the inflammation extends into the surrounding tissue. The places of attachment of the exudate were probably points where small groups or single alveoli opened into the bronchiole. Purulent infiltration of the submucous tissues. Streptococci and Gram-negative bacteria in the pus. This bronchiole was the center of a peribronchiolar, nodular consolidation. Accession number 2694, Army Medical Museum. Negative number 46028. Hematoxylin and eosin stain; × 170