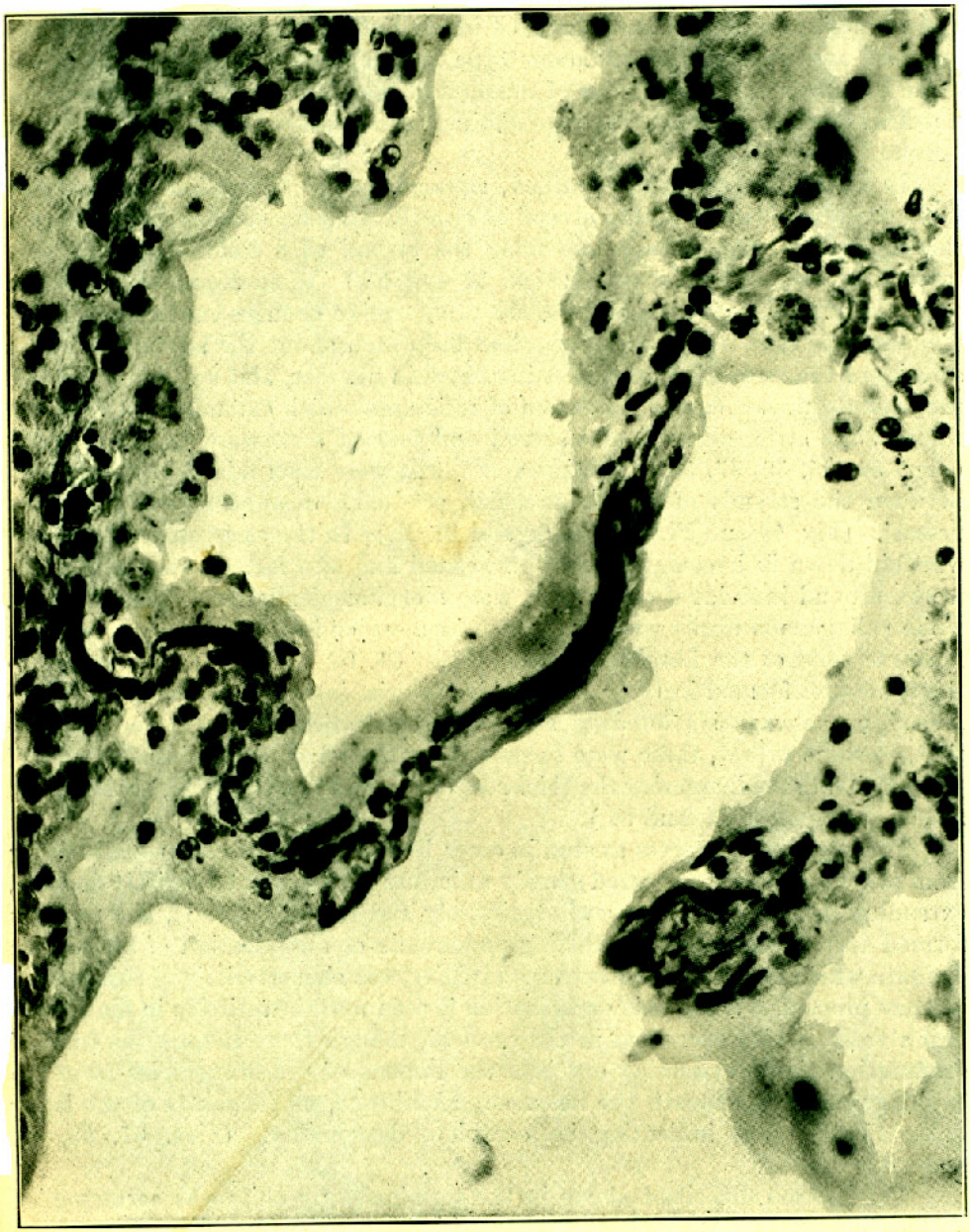

FIG. 36.—Degenerated wall of atrium. Swollen elastic tissue, stained dark, in a necrotic amorphous wall. Accession number 1519, Army Medical Museum. Negative number 45221. Elastic stain; × 555