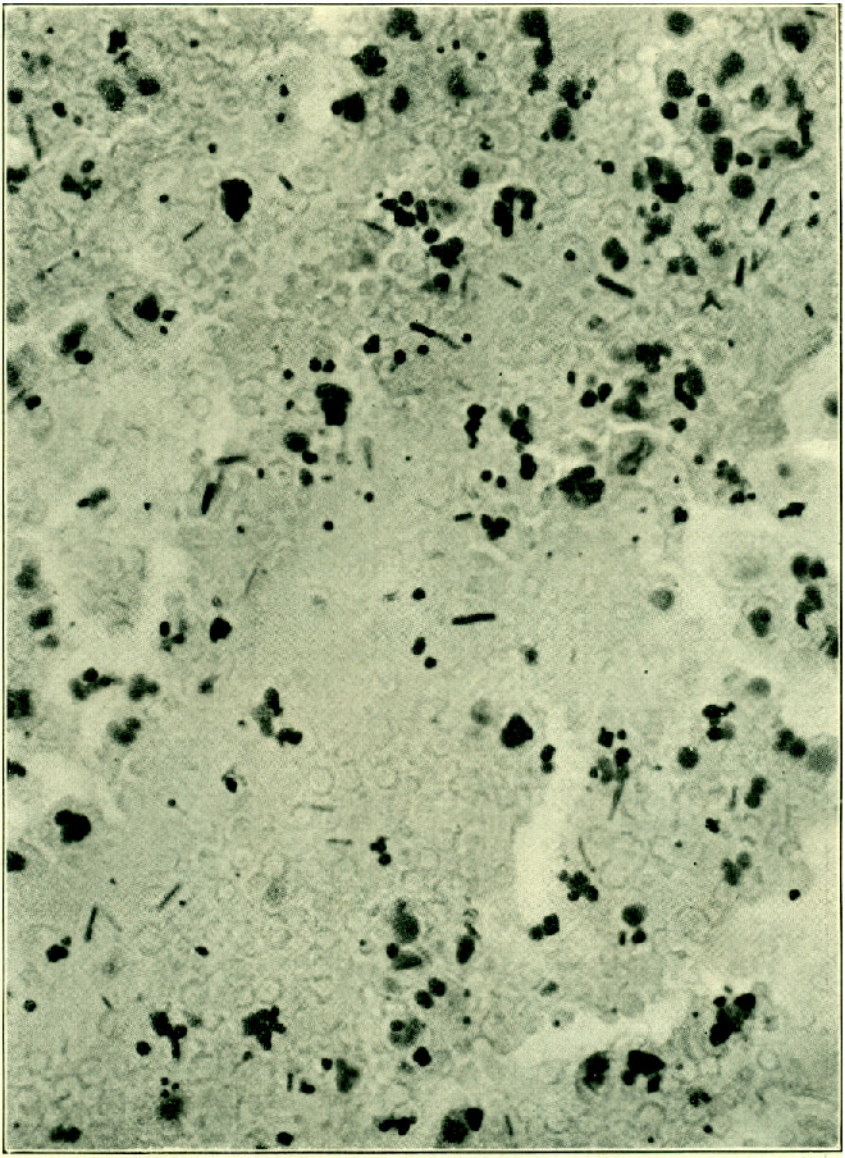

FIG. 306.—Field of the hemorrhage in the gangrenous area which contains numerous cocci and rod-shaped bacteria. There are no forms which appear like the uniform round-ended Welch bacillus, which probably accounts for the small amount of gas in this case. Accession number 4717, Army Medical Museum. Negative number 46068. MacCallum stain; × 870