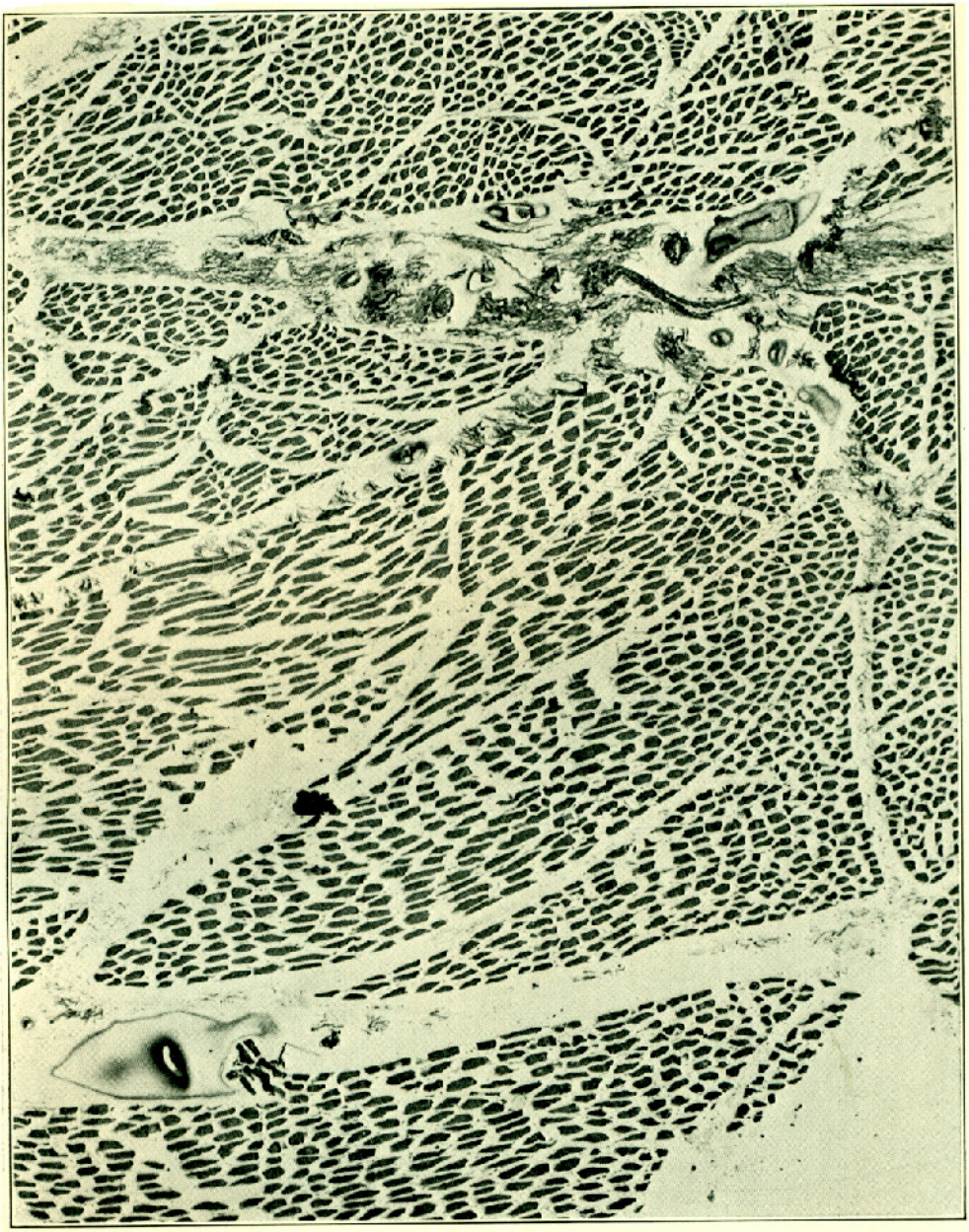

FIG. 260. Section from the margin of the gangrenous reactions around the fracture. There is marked edema along the fascial plane in the upper portion of the picture and a large accumulation of edema fluid in the lower left-hand area. There is beginning accumulation of gas between muscle bundles. Accession number 2891, Army Medical Museum. Negative number 45631. Hematoxylin and eosin stain; × 23