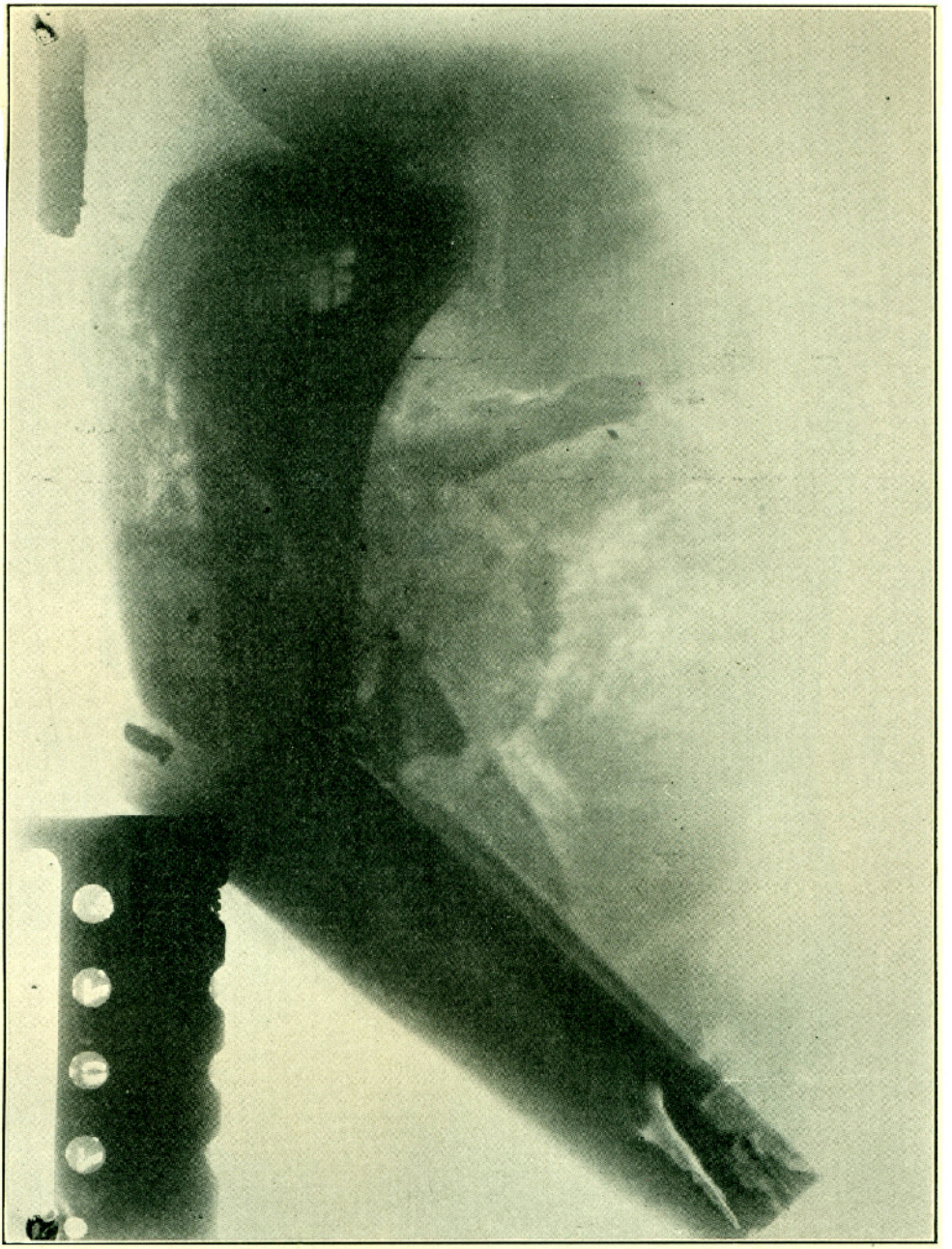

FIG. 217.—X ray, showing the fractured tibia and fibula displaced forward and a massive irregular gas gangrene of the calf muscles behind it. Accession number 4707, Army Medical Museum. Negative number 46245