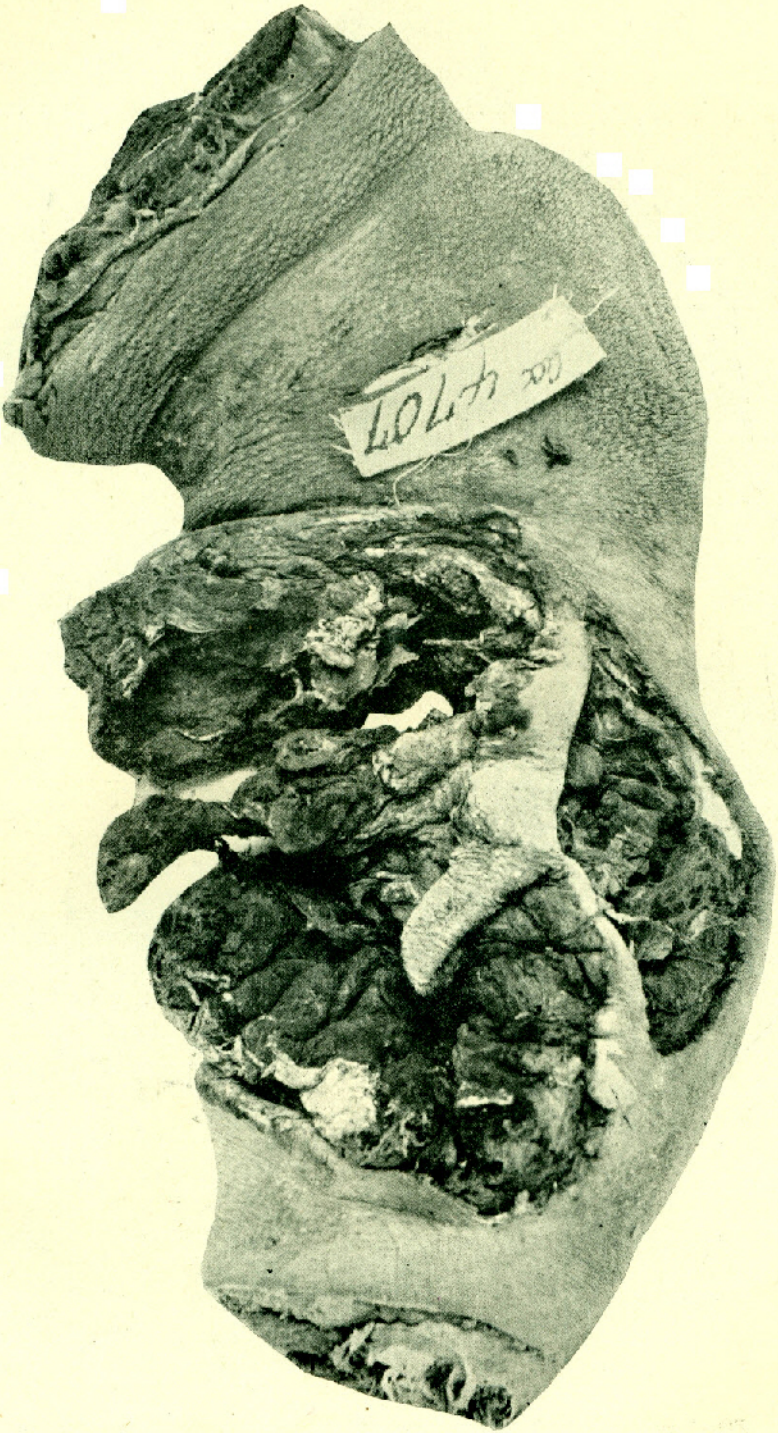

FIG. 215.—High-explosive shell wound caused by contact explosion. Muscle completely pulped. Accession number 4707, Army Medical Museum. Negative number 30236