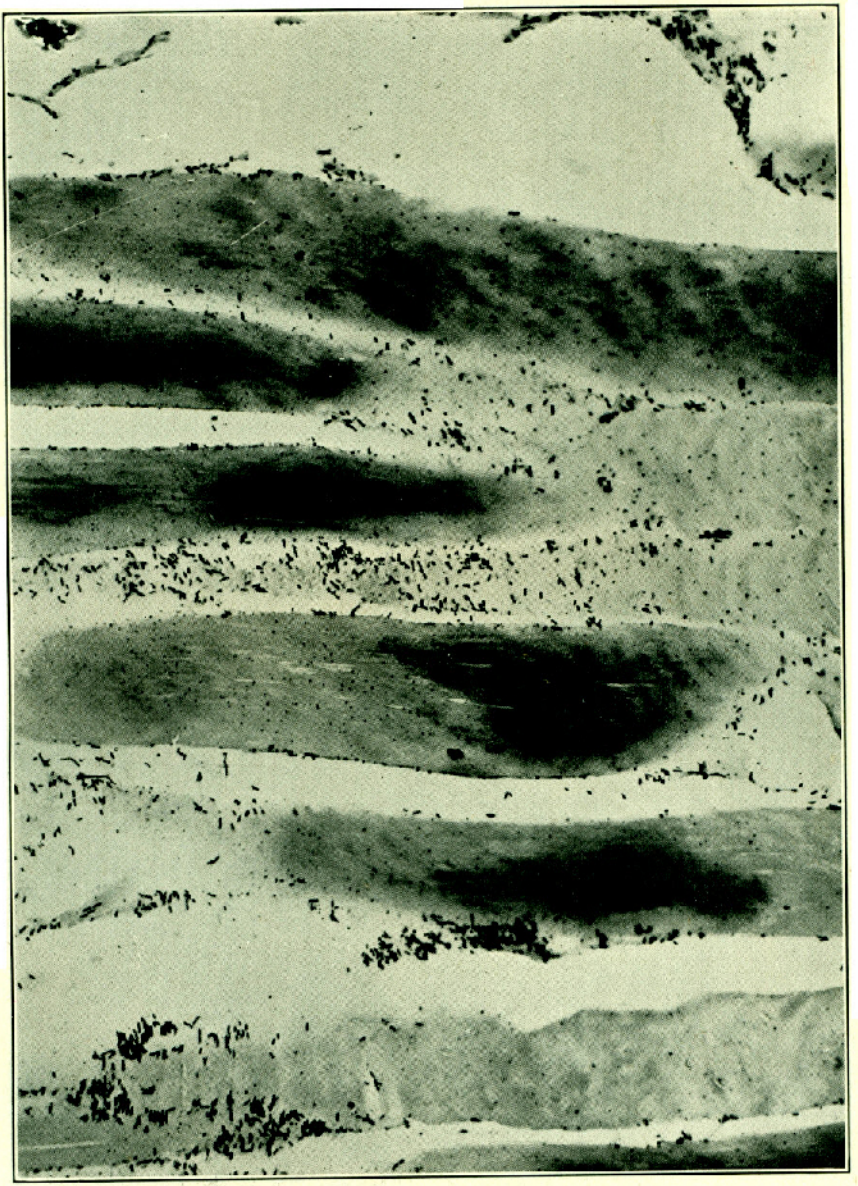

FIG. 177.—Longitudinal section of muscle fiber taken from the contaminated area of muscle infection near the débrided wound. The muscle fibers are dotted with a fine débris of blood pigment. The lesion is a gaseous one with a superimposed putrefactive process. The bacteria seem to be of one type and are probably Welch bacilli. The muscle fibers show a retention of the basic dye. Accession number 2879, Army Medical Museum. Negative number 46057. MacCallum stain; × 205