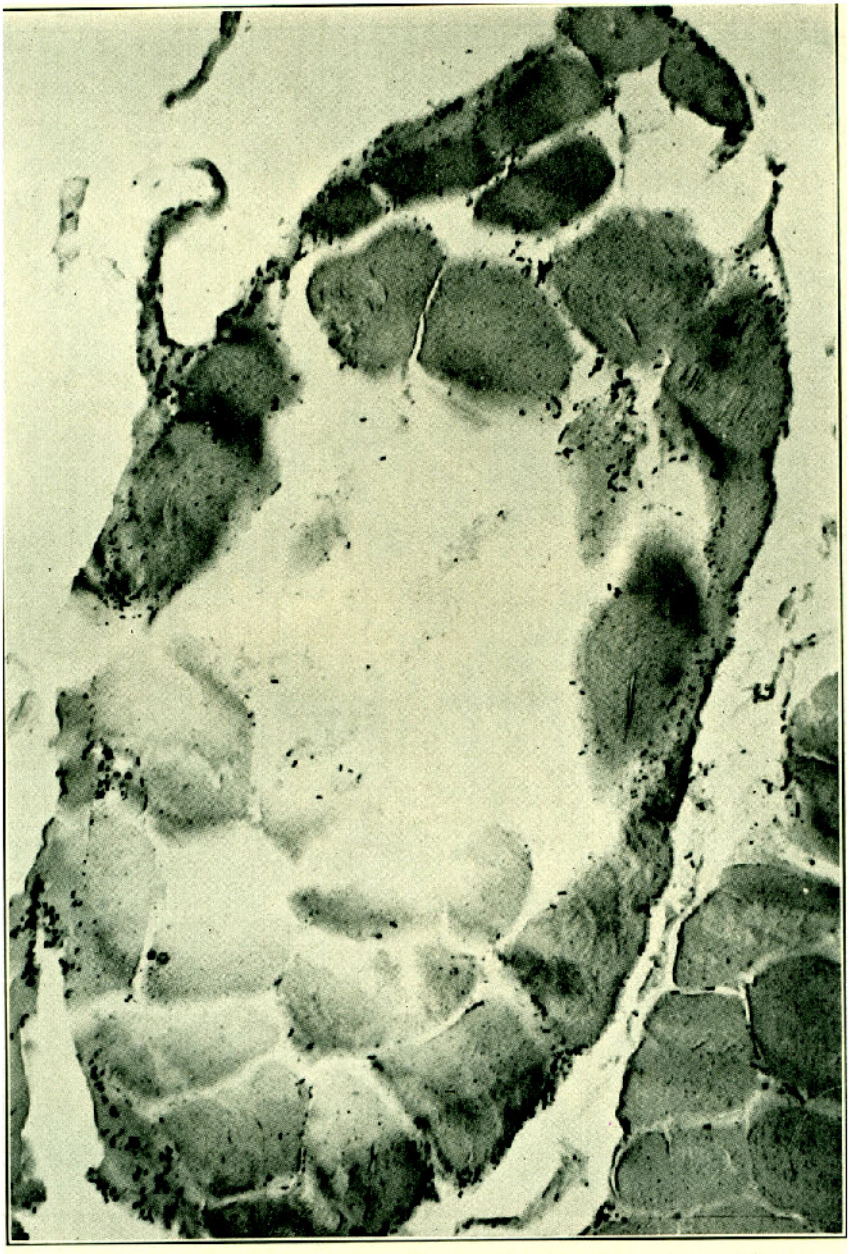

FIG. 173.—Gangrenous area, showing the central wo-thirds of a small muscle bundle replaced by gas. The margins of the bundle contain numerous Gram-positive round-ended rods. These are less frequent in the central area. This appears to be a pure infection with *B. welchii*. There is no leucocytic infiltration in this section. Accession number 2879, Army Medical Museum. Negative number 46045. MacCallum stain; × 305