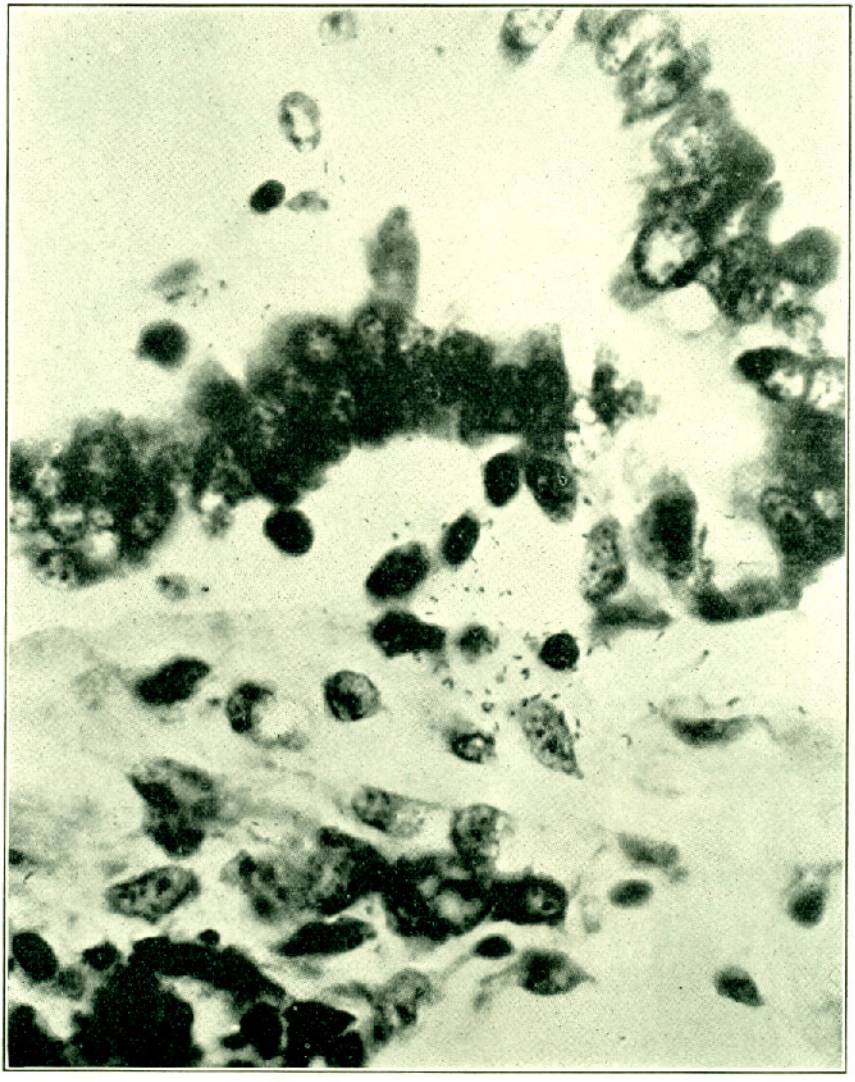

FIG. 17.—Wall of bronchiole. Epithelium being raised and separated by serous exudate beneath. Gram-negative minute bacilli and mononuclear cells in exudate. Accession number 3108, Army Medical Museum. Negative number 45270. MacCallum stain; × 1300