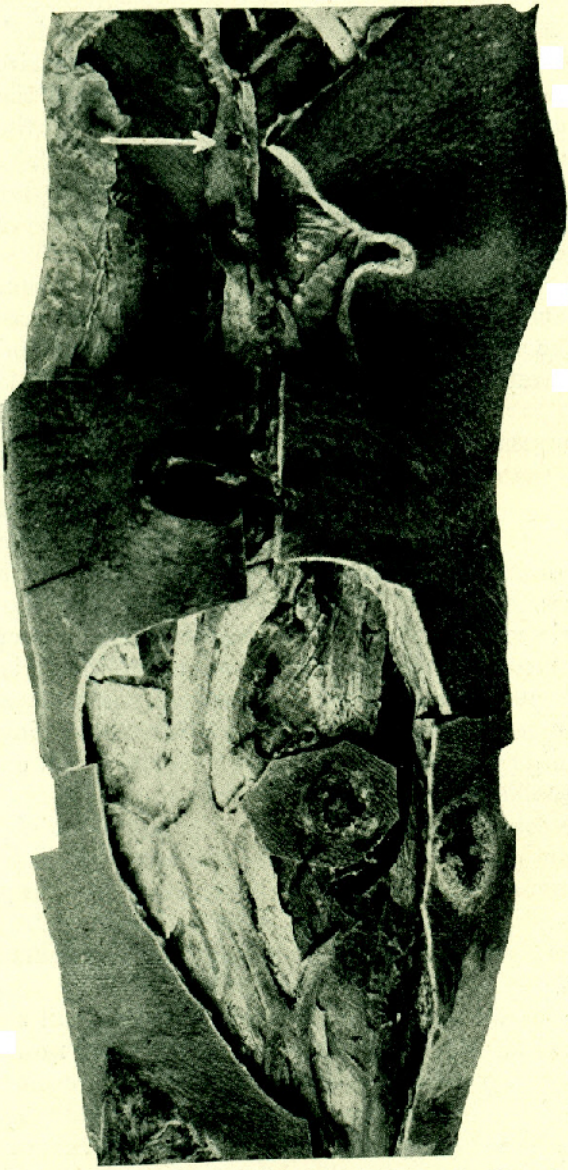

FIG. 168.—Posterior aspect of left leg amputated for a mixed type of gas gangrene, with extensive putrefactive blackening of the inner and posterior aspect of the upper two-thirds of the calf. There are several high-explosive wounds on the posterior surface, around which there has been superficial dissection of the skin in the search for injuries to vessels and subcutaneous hemorrhages responsible for this zone of gangrene. Seven and one-half centimeters above the uppermost wound is a rupture of the long saphenous vein, probably produced by the missile through hydraulic transmission of its force. Arrow points to rupture. Accession number 4720, Army Medical Museum. Negative number 30237