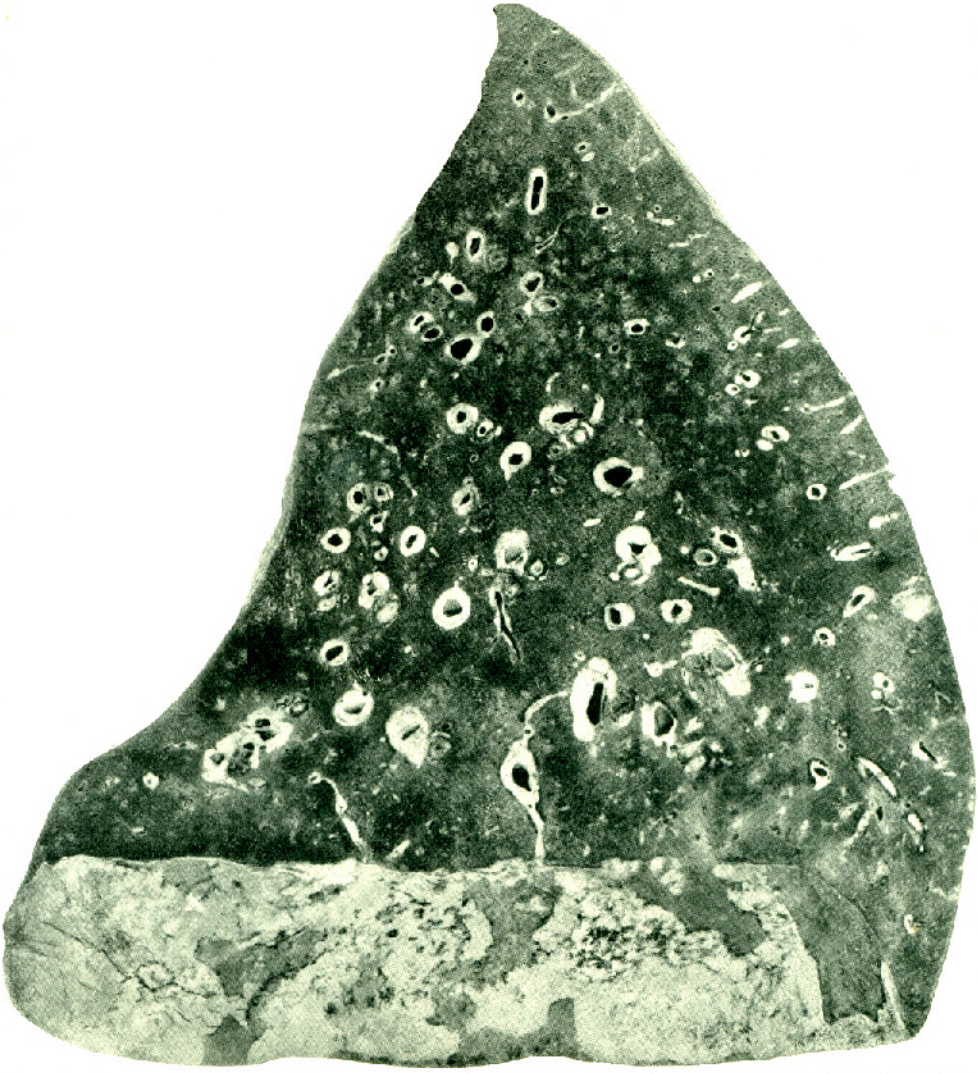

FIG. 148.—Pneumonia following influenza complicated by empyema. Hemolytic streptococci in cultures from the lung and pleura. Section shows bronchi and arteries cut in cross section to show the rings of peribronchial and perivascular lymphangitis. Accession number 3047, Army Medical Museum. Negative number 42905