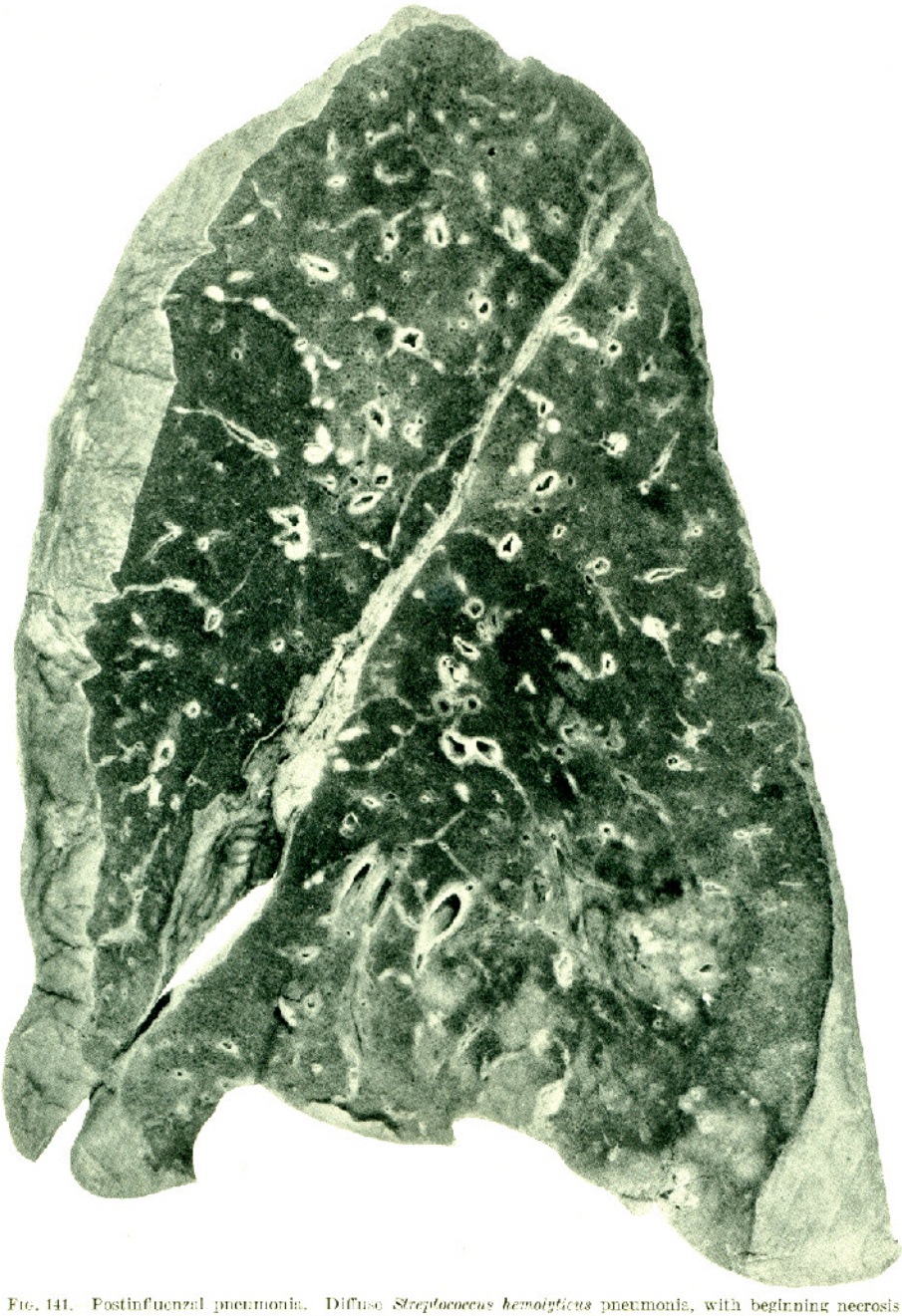

FIG. 141. Postinfluenzal pneumonia. Diffuse *Streptococcus hemolyticus* pneumonia, with beginning necrosis in areas surrounding smaller bronchi in the base of the lower lobe. Considerable peribronchial and perivascular lymphangitis, most marked about the bronchi and arteries in the upper lobe. The interstitial tissues show nodular areas of pus accumulation and necrosis, giving them a beaded appearance. Accession number 3082. Army Medical Museum. Negative number 42868