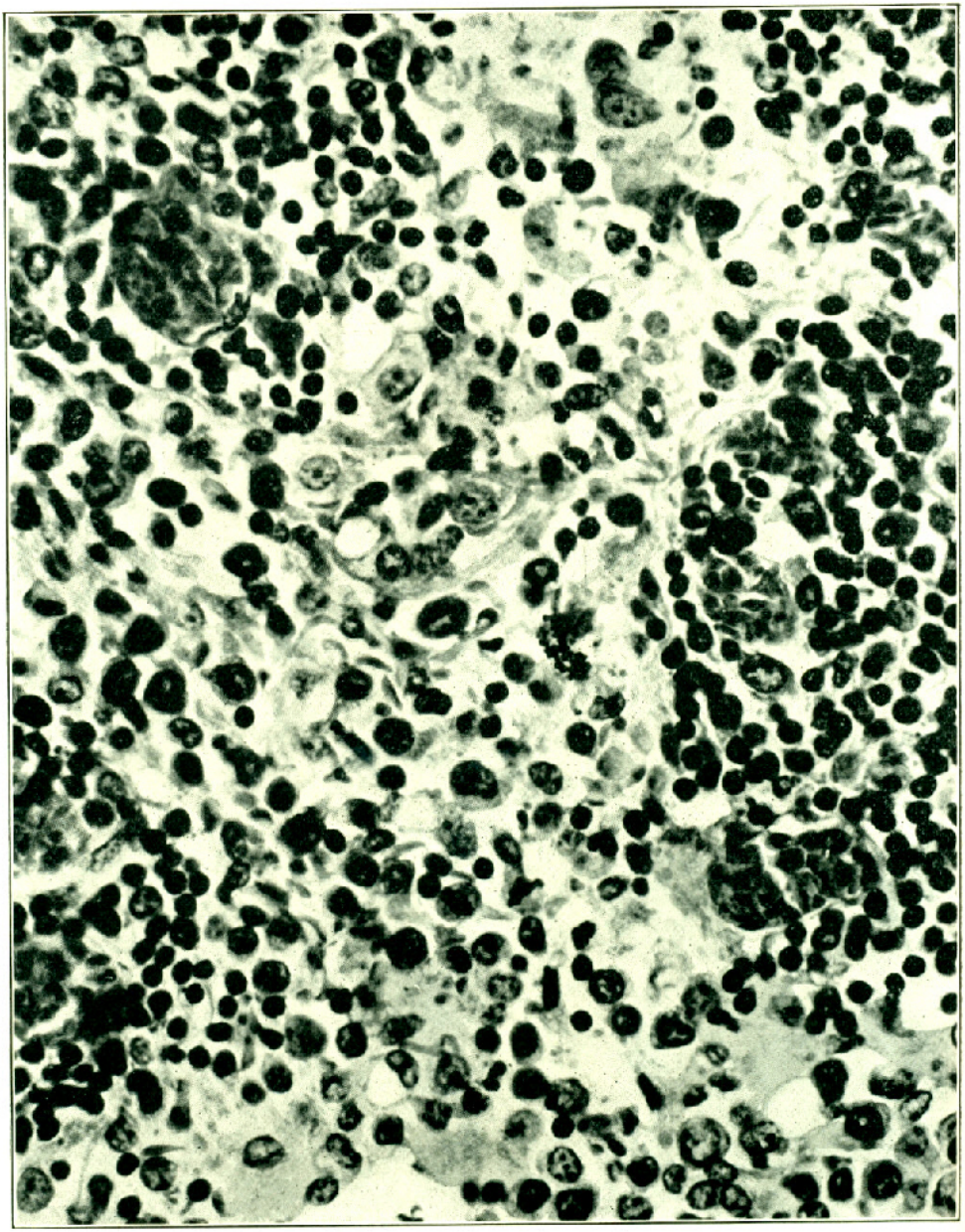

FIG. 11.—Cellular reaction in a bronchial lymph node in pneumonia following influenza, showing the character of the cell exudate along the reticular tissue of the node. Very few polymorphonuclear leucocytes are seen, lymphocytes are moderately numerous, while large mononuclear cells preponderate; they were evidently actively proliferating as indicated by mitotic figures. Accession number 1049, Army Medical Museum. Negative number 45170. Hematoxylin and eosin stain; × 580