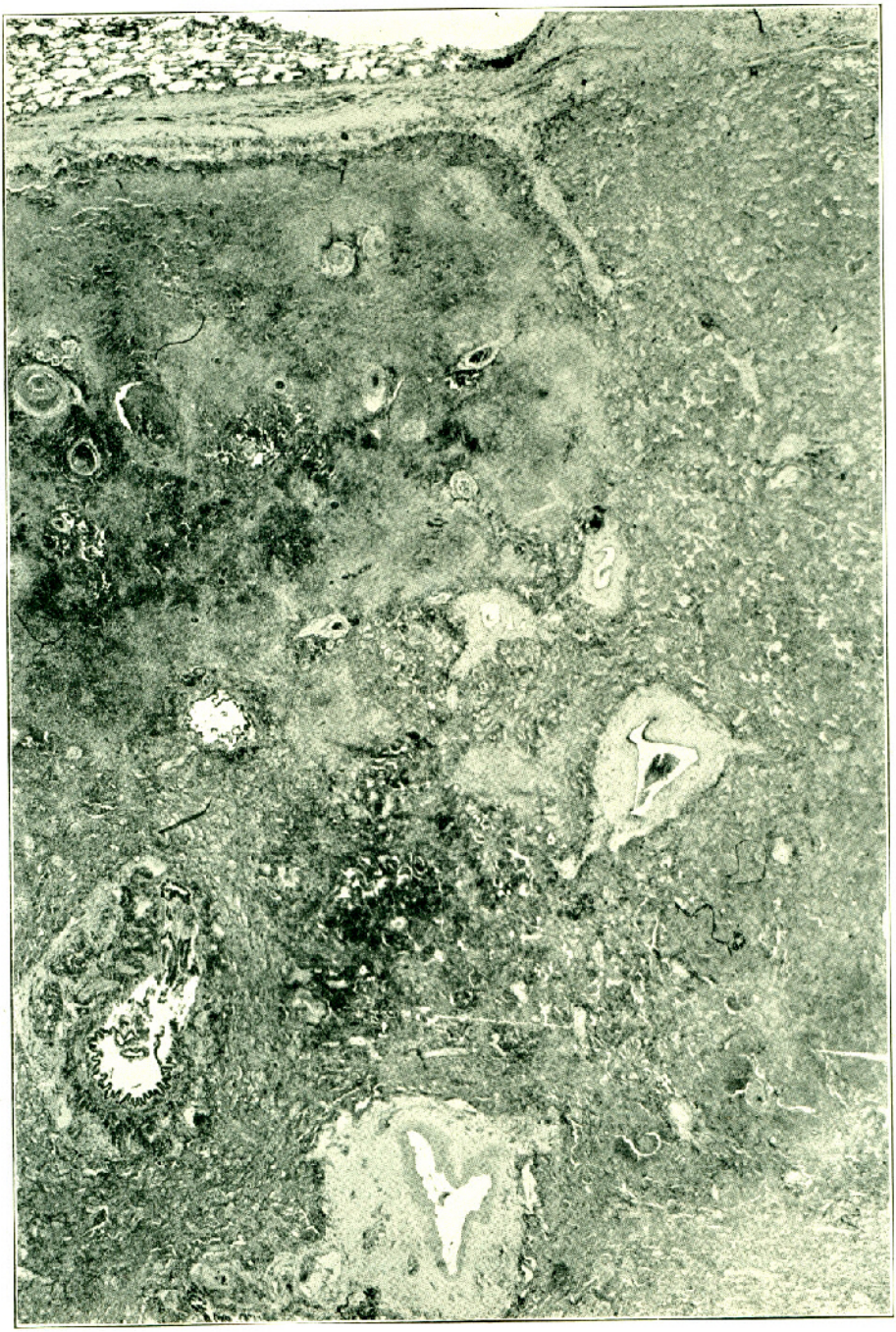

FIG. 101.—Lobular pneumonia. Nonhemolytic streptococcus in culture. Necrosis further advanced near interlobular septum. Phlegmon about vessels and bronchioles. Accession number 3026, Army Medical Museum. Negative number 45219. Hematoxylin and eosin stain; × 24