The Experience of a Unit Dental Officer During the Gulf War

CPT William P. Baker†
LTC Dan Pietz††

Introduction

During Operation Desert Storm, United States (U.S.) and Allied ground troops enjoyed great success. The ground war was characterized by rapid troop movement which presented a challenge for dentists assigned to the divisions participating in the ground war. This article will address the experience of one dental officer assigned to a division during the Gulf War and the dental lessons learned from this experience.

Dental Doctrine

Under current doctrine, dental support is designed using a modular concept to provide flexibility and allow easy augmentation, reinforcement, or reconstitution of dental assets. A dental module consists of a dental officer, dental assistant, compact, and high technology equipment. Unit dental support is the most forward dental support and is provided by the dental module organic to Echelon II medical units. Echelon II medical units provide emergency care and advanced trauma management. At division level, the medical companies of the forward and main support battalions provide Echelon II medical support. The unit dental module is assigned to the area support squad of medical companies in divisions, separate brigades, armored cavalry regiments, and area support medical battalions.[1]

The primary objective of unit dental support is to return the soldier to duty as rapidly as possible consistent with the tactical situation. Each unit dental officer provides dental care and functions as the dental surgeon for the supported unit. The dental officer assigned to a forward support battalion (FSB) is a general dentist (CPT, 63A) who serves as the Brigade Dental Surgeon (BDS). The dental officer assigned to the main support battalion (MSB) is a comprehensive dentist (MAJ, 63B) who serves as the Division Dental Surgeon (DDS).[2]

During the Gulf War, the table of organization and equipment for the dental module in a heavy division included the following equipment: two dental chairs with stools, two operating units, two compressors, two dental supply chests, two general supply chests, portable dental X-ray machine, X-ray developer, X-ray supply chest, sterilizer, and a surgical sink unit. The dental equipment was stored and transported in an expando-van mounted on a 5-ton truck. The truck pulled a trailer-mounted, 10-kilowatt diesel generator. (Figures 1 and 2).



Fig 1. Exterior of fully expanded truck.

Personal Experience

The primary author deployed from Nuernberg, Germany, to Saudi Arabia as a member of the 87th Medical Detachment (MED DET) (HA). A MED DET (HA) was similar to the current Medical Force 2000 Medical Company (MED CO) (DS). A MED DET (HA) was an Echelon III dental unit with a mission of providing all categories of dental treatment up to maintaining care on an area basis. A secondary mission was to reconstitute and/or reinforce division dental assets. It was this mission that provided me the opportunity to serve as a unit dental officer with two FSBs of a heavy division during Operation Desert Shield/Storm.

I volunteered to replace the dental officer assigned to the 122d MSB, 3d Armored Division, who was unable to deploy with his unit because of recent

† Dental Corps. General Dentistry Officer, U.S. Army DENTAC, Fort Drum, NY.

†† Dental Corps. Chief, Professional Development Branch, Department of Dental Science, Academy of Health Sciences.

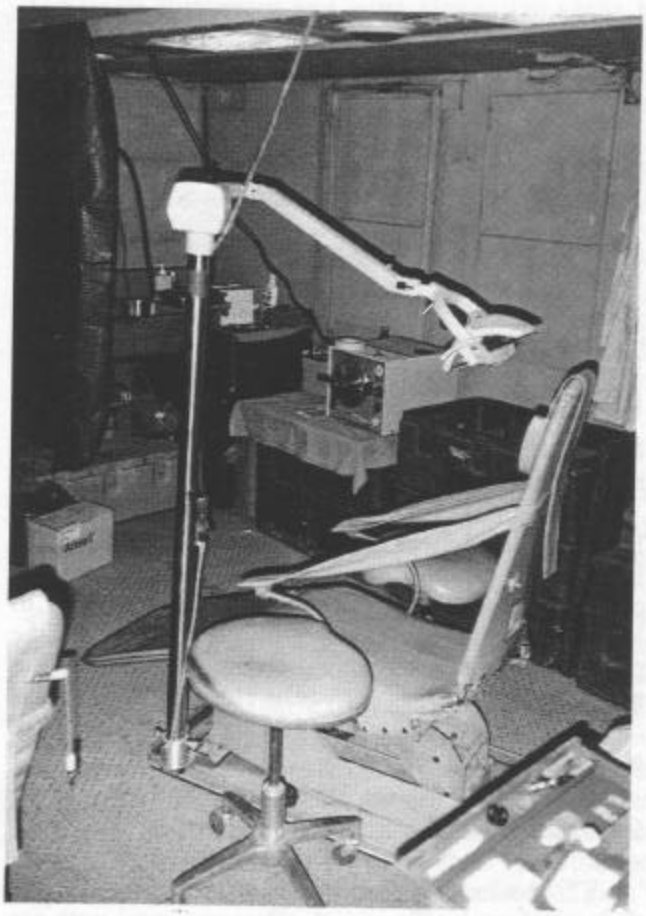

Fig 2. Interior view of the dental van.

surgery. The 87th MED DET (HA) was attached to VII Corps and was responsible for reconstituting its division dental assets. I joined the unit 2 days after the start of the air campaign and remained with it until the unit moved to the forward assembly area to prepare for the ground campaign. Immediately before the ground war, the dental officer assigned to 45th FSB had to return to the U.S. because of an emergency. I was then attached to this unit and stayed with it until after the cease-fire.

Before the air campaign, VII Corps units were located in their respective tactical assembly areas (TAA). Here, unit personnel adjusted to a new environment and trained for the upcoming ground war. Dental support was accomplished easily during this time because the medical company remained in one location. I provided emergency dental treatment on a sick call basis and saw an average of four to six soldiers daily. The patients presented with one of three general chief complaints: cracked or fractured restorations, symptomatic erupting third molars, or decayed and abscessed teeth.

Before the ground war, the FSB Commander made several decisions on how to efficiently use the battalion's assets. The main concern was how to manage the large number of expected casualties. One solution was to convert the dental expando-van into an advanced trauma life support section and leave the dental equipment at the TAA. This plan was not used because the dental van became mechanically disabled and the battalion commander refused to take it into Iraq. A logistics base near the unit's TAA served as a holding area for this vehicle and others awaiting repair.

Faced with this situation, I had to develop an alternative means for providing emergency dental care. The primary factors considered in making this decision were:

1. It would take at least 2 hours to set up a one-chair dental facility using the assigned dental equipment.

2. A vehicle was needed to transport the dental equipment which required at least 25 square feet of storage space.

3. Electrical power was required to run the dental equipment.

These factors made it difficult to provide dental care using the assigned field dental equipment. An alternative means of delivering dental care was developed using a medic aid bag to carry needed dental instruments. I placed the following items in the aid bag: Nos. 34 and 301 elevators, Nos. 150 and 151 forceps, 4-O resorbable suture, needle holders, scalpel handles, sterile gauze, an assortment of endodontic files (sizes 8, 10 15, 20, 25), endodontic broaches, spoon excavators, a glass mixing block, cement spatula, reinforced zinc oxide and eugenol cement (Intermediate Restorative Material), glass ionomer cement (Ketac Cement), 3 types of anesthetic agents: 2% Xylocaine (Lidocaine)) with 1:100,000 epinephrine, 0.5% Bupivacaine (Marcaine) with 1:200,000 epinephrine and 2% Mepivacaine (Carbocaine) with 1:20,000 Neocobefrin, and 1 container each of saline and sterile water.

Although I had to improvise an emergency dental instrument set, this may not be necessary in the future because of the recent addition to the modified table of equipment (MTOE) of a Dental Instrument and Supply Set (DISS) and Emergency Treatment. Unit dentists should anticipate providing dental treatment under austere conditions using the DISS and Emergency Treatment and augmenting it to fit the situation.

Two days before the ground campaign started, the 45th FSB was placed on 2-hour alert (Figure 3). The short alert notice made it impossible to set up the dental equipment, but it did not prevent soldiers from receiving dental care. Patients sat on a regular folding chair during treatment (Figure 4) and the dental assistant provided the light source with a pocket flashlight. I used the improvised emergency dental set to provide treatment so the soldier could return to his unit and perform his mission without limitations. Under these circumstances, narcotic analgesics for dental pain control were contraindicated because they could impair a soldier's ability to function.

Fig 3. Brigade line up 2 days prior to the ground campaign, 10 km from Iraq border.

Fig 4. Giving postoperative instructions to a patient.

During the ground war, no soldiers reported to the medical company for dental treatment. I was used in an alternate wartime capacity serving as the triage officer, initiating IV fluids for the advanced trauma life support teams, and treating minimal care casualties (Figure 5). I was well prepared and felt confident that

Fig 5. Providing emergency medical care to a wounded soldier.

I could perform these alternate wartime duties because I had attended the combat casualty care course and chemical casualty care course before deploying to Southwest Asia (SWA). Also, I trained daily with the physicians and physician assistants assigned to the medical company. Fortunately, there were no mass casualties situations and our medical capabilities were never exceeded.

Lessons Learned

There were four areas that caused problems for the unit dental officer and affected dental care for supported soldiers. The following discussion will deal with identifying these problems, discussing their impact, and recommending a way to avoid them in the future.

First, approximately one-third of the patients presented with a chief complaint of pain associated with a mandibular third molar. Performing extractions under field conditions provides many challenges for the dental officer because of the equipment and environment. The field environment is also a harsh one for post extraction patients. The living conditions and work situation interfere with the normal healing process and increase the risk of infection. For these reasons, dental officers should make every effort before deployment to evaluate third molars and extract them when appropriate.

Second, although the desert was a harsh environment, the dental van provided an excellent facility for delivering quality dental care. The van provided climate controlled conditions and could be ready for patient treatment within 2 hours after arriving at a new site. A drawback to the van is that it may be deadlined or inoperable. The unit dentist needs to

anticipate this event and have alternative plans to provide dental care. The current MTOE for the unit dental module includes a dental instrument and supply set, emergency care. This set has the basic instruments for extractions, materials for placement of temporary restorations, and a battery operated handpiece. This handpiece allows the dental officer to section teeth for extraction, remove caries, and initiate endodontic therapy. However, there are two limitations when using the handpiece: the need for electricity to charge the battery and the time and effort required to disinfect or sterilize the handpiece. The unit dental officer needs to anticipate and plan for equipment shortages or other situations that may limit dental care.

Third, the Division Medical Supply Office (DMSO) was frequently unable to meet dental supply needs in two areas. First, there were shortages of commonly used items, such as amalgam, local anesthetic, periapical film, and disinfecting solution. Second, the DMSO stocked dental materials similar to those used during the Vietnam War. Although these materials were effective for treating most dental emergencies, more modern materials would have permitted the dental officer to provide a higher standard of care. The most significant problem was the lack of composite (tooth colored) restorative material which was needed on several occasions to repair fractured anterior teeth. Since the DMSO didn't stock composite, treatment options were limited for soldiers with fractured anterior teeth. Although it was not an ideal replacement, I used glass ionomer cement (Ketac Cement) as a temporary restoration. Sources outside the division medical supply system provided this material.

The dental supplies stocked by the DMSO should be changed to reflect the type and quantity of dental supplies needed during deployments. The solution for this problem is to have the Dental Consultant from the Directorate of Combat and Doctrine Development change the unit assemblage list (UAL) for the unit dental module to reflect current dental practices. The following items should be added to the UAL: self-curing acrylic resin, stainless steel crowns, polycarbonate anterior crowns, glass ionomer cement, a light cured glass ionomer, a light cured composite restorative material, and a curing light source.

One reason for the inadequate quantity of dental supplies stocked by DMSO is that the unit dental officer frequently obtains dental supplies from the local dental treatment facility (DTF) to support training exercises. By using this "unofficial" supply source, the dental officer doesn't communicate to DMSO the appropriate quantity of dental supplies needed. During short deployments, such as a field training exercise, this "unofficial" system works well. However, during long-term deployments, supply problems develop once the initial stock of materials obtained from the DTF is gone. The unit dental officer should order dental supplies through DMSO to support field training exercises. This practice will help establish realistic quantities of dental supplies carried by DMSO because it uses a "demand based" system to determine the quantity of supplies carried.[3] During deployment and in an extreme emergency, the unit dental officer can obtain dental supplies from Echelon III dental units: the MED CO (DS) or MED DET (DS). These dental units are normally found in the corps area where they provide sustaining and maintaining care on an area basis. These units stock a wider range of dental supply items and can serve as an emergency source of dental supplies. To accomplish this supply effort, requires open lines of communication between the division dental assets and Echelon III dental units.

Fourth, there was a lack of technical supervision of division dental assets in at least two of the VII Corps' divisions. By doctrine, the DDS is assigned to the MSB and is a Major with an area of concentration of 63B, indicating he or she has graduated from an Advanced Education in General Dentistry 2-year residency program. The DDS serves as a dental consultant to the division commander and acts as a mentor and a point of referral for the BDS. In SWA, the dental officer assigned to the 3d Armored Division's MSB was a Captain, who had not completed a 2-year residency program. Although he was a qualified dentist, this dental officer didn't have the training or experience to function as a DDS or provide referral service for the BDS. Consequently, soldiers with significant dental problems had to be evacuated for treatment to a hospital in the corps area. The dental officers in the FSB felt isolated because there was no referral facility or input for division dental issues. The solution for this situation is to assign a comprehensive dentist (63B) in the rank of Major or above as the DDS.

Conclusion

Although this article addresses the experiences of one unit dental officer during Operation Desert Shield/Storm, the lessons learned apply to any deployment. The suggestions presented may help unit dental officers prepare for problems they may encounter during future field exercises and deployments. The

most important suggestion is for the unit dental officer to order supplies through DMSO to support routine training exercises. The unit dental officer is the officer-in-charge of dental operations for the brigade and plays a critical role in support of assigned troops. Successful dental support requires much thought and preparation before deployment.

References

1. FM 8-10-9, Dental Service Support in a Theater of Operations, p 2-1, Headquarters Department of Army, Washington, DC, 12 May 1993.

2. FM 8-10-19, Dental Service Support in a Theater of operations, p 2-1, Headquarters, Department of the Army, Washington, DC, 12 May 1993.

3. The Division Medical Supply Office Handbook, p F-3, Academy of Health Sciences, U.S. Army, Fort Sam Houston, TX, March 1989.